Low-Dose CT: Clinical Studies & the Radiologist Perspective

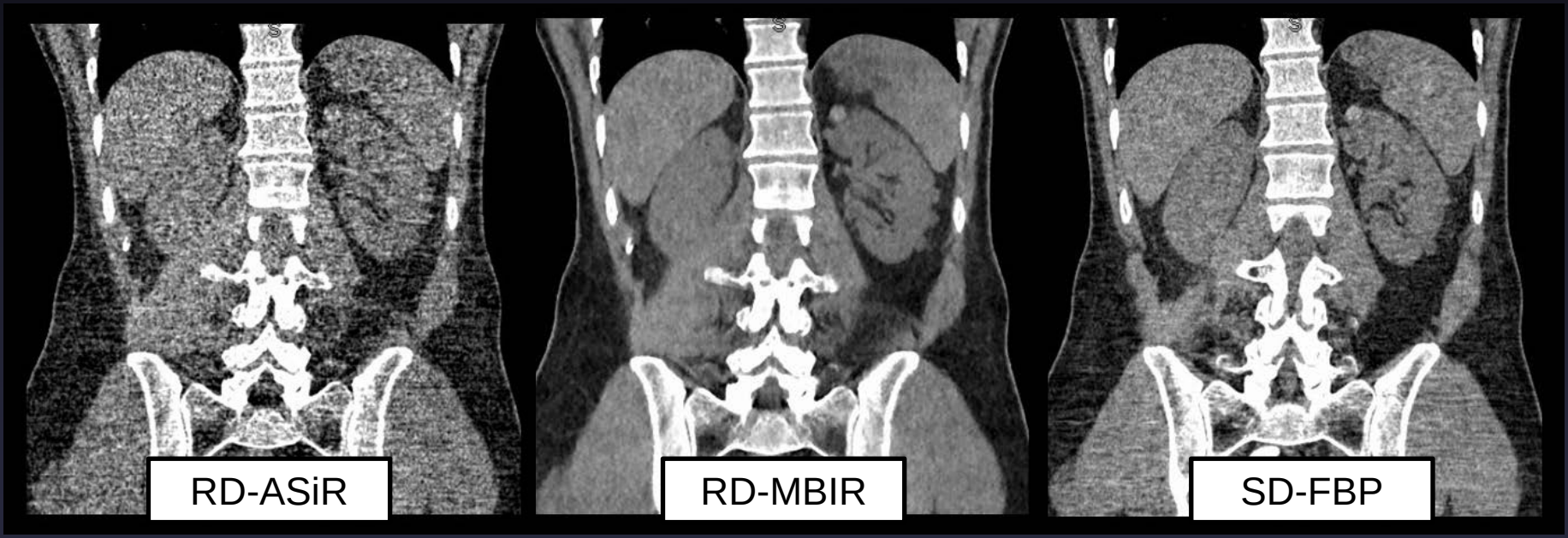

RD=0.35 mSv (80% dose reduction)

Perry J. Pickhardt, MD
UW School of Medicine & Public Health

Low-Dose CT: Clinical Overview

- Is there any real clinical benefit to dose reduction?
- Given the perceived risk, ALARA applies
- Dose reduction targets should be indication specific and should not degrade performance
- Neither subjective nor objective measures of “image quality” necessarily equate with diagnostic accuracy in clinical practice
- Dose optimization is an iterative process

Risks of Low-dose Radiation

- HPS Position Statement:
  - *2010:* "Below 50-100 mSv, risks of health effects are either too small to be observed or are nonexistent"
  - *2016:* "Below levels of about 100 mSv above background from all sources combined, the observed radiation effects in people are not statistically different from zero"
- Experience with radiation workers, airline pilots, TB patients, radon levels, etc:
  - No increase in cancer rates from low-level exposures
- Is the "linear no-threshold" (LNT) theory valid?

Death from Breast Cancer in TB Patients Treated with Pneumothorax (n = 25,007)

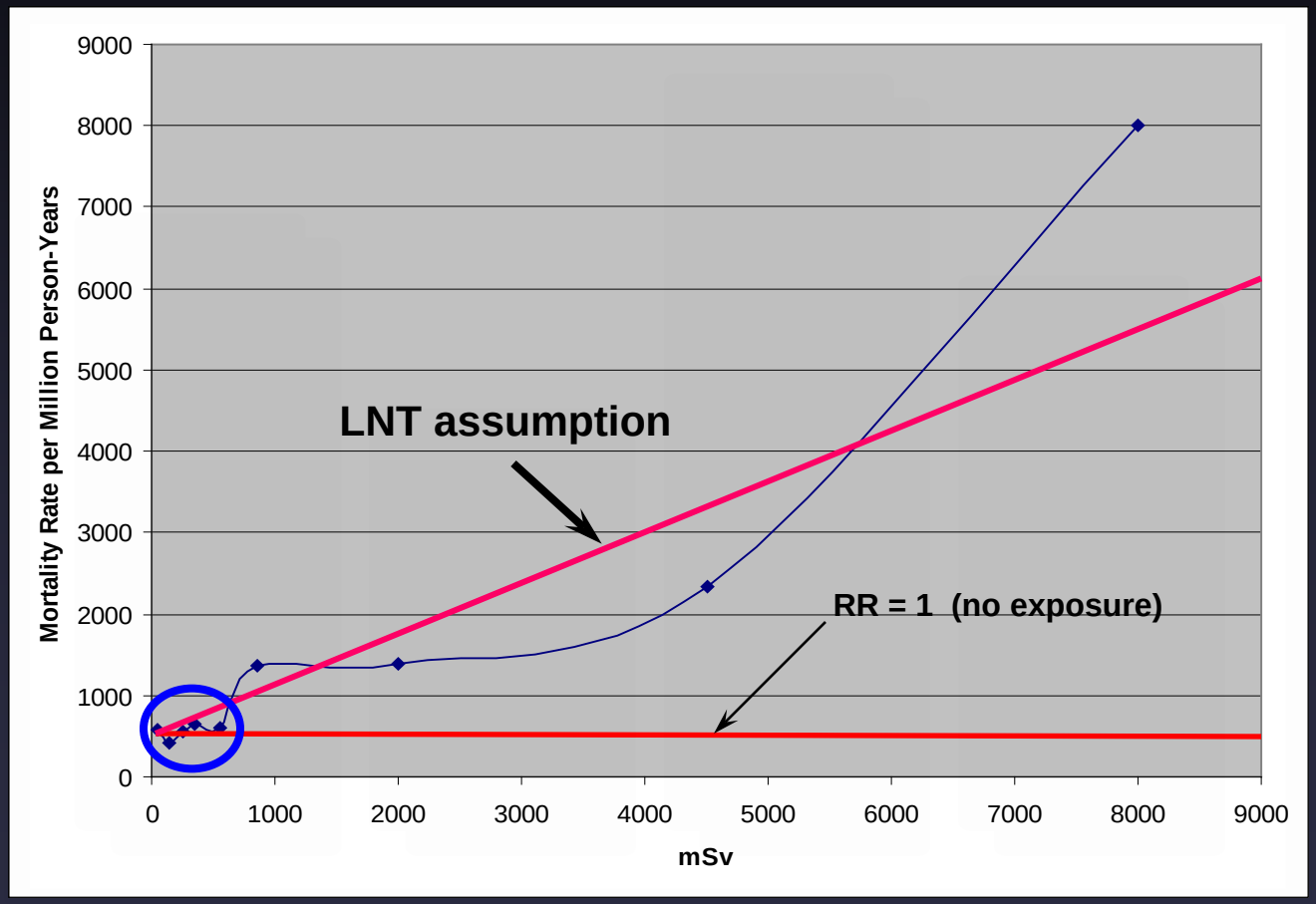

Miller AB et. al. Mortality from Breast Cancer after Irradiation NEJM 1989; 321:1285-1289

Death from Breast Cancer in TB Patients Treated with Pneumothorax (n = 25,007)

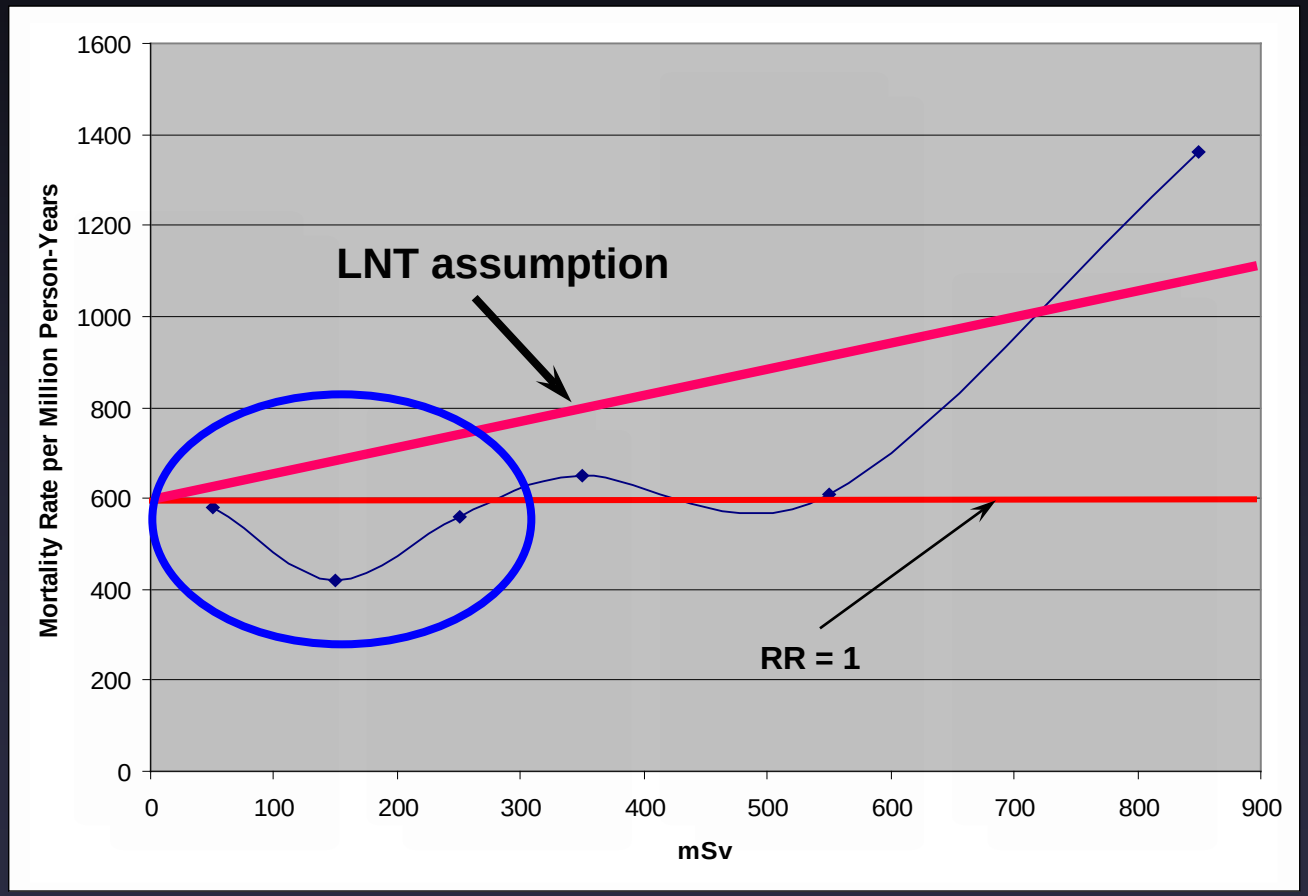

Miller AB et. al. Mortality from Breast Cancer after Irradiation NEJM 1989;321:1285-1289

Medical Physics
The International Journal of Medical Physics Research and Practice

Proposition: Radiation hormesis should be elevated to a position of scientific respectability

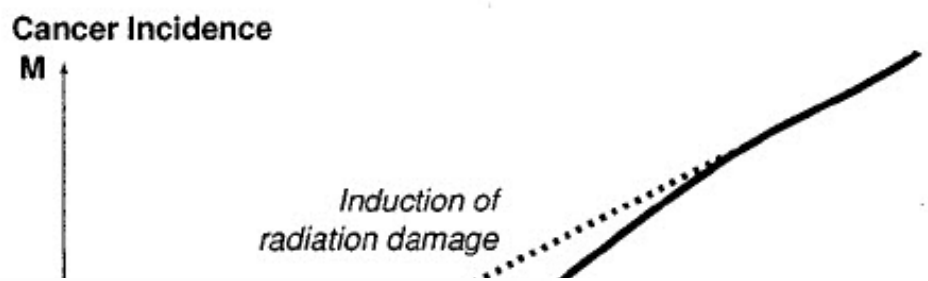



JNM
January 1, 2017; 58 (1)
The Journal of Nuclear Medicine
SPECIAL CONTRIBUTIONS

Subjecting Radiologic Imaging to the Linear No-Threshold Hypothesis: A Non Sequitur of Non-Trivial Proportion

Jeffry A. Siegel[1], Charles W. Pennington[2], and Bill Sacks[3]

Radiation Exposure from CT

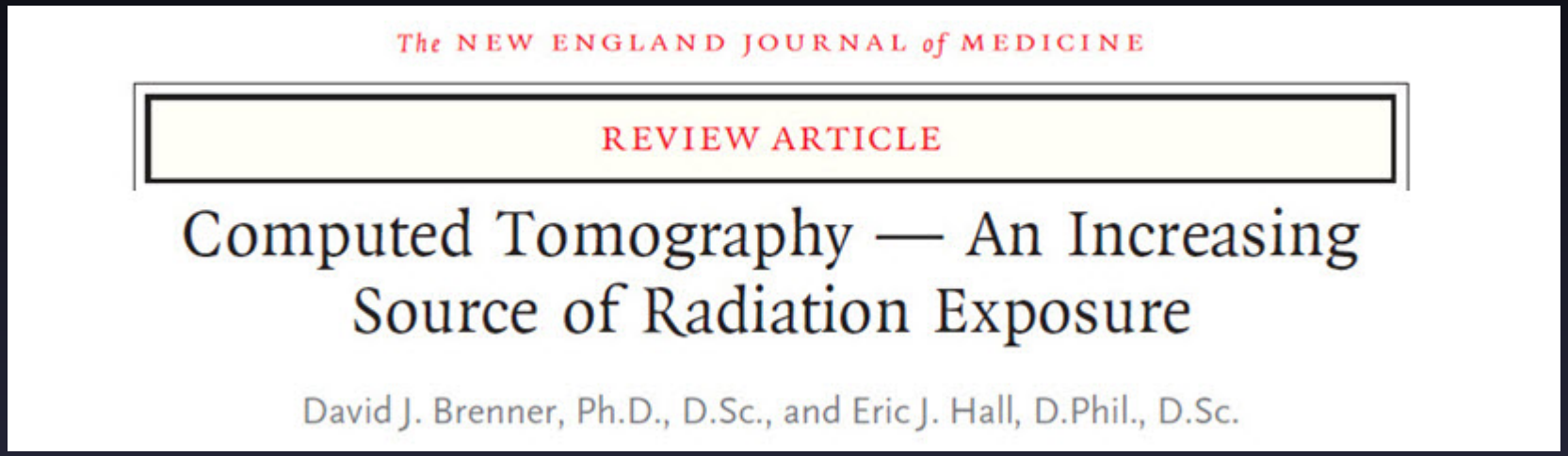
The NEW ENGLAND JOURNAL of MEDICINE

REVIEW ARTICLE

Computed Tomography — An Increasing Source of Radiation Exposure

David J. Brenner, Ph.D., D.Sc., and Eric J. Hall, D.Phil., D.Sc.

- 2007 review article
  - >3200 citations per WoS; >5500 per Google Scholar
- ~100 million scans performed each year in the U.S.
- CT is one of the greatest advances in medicine
- Are we a victim of our own success?

Radiation Exposure from CT

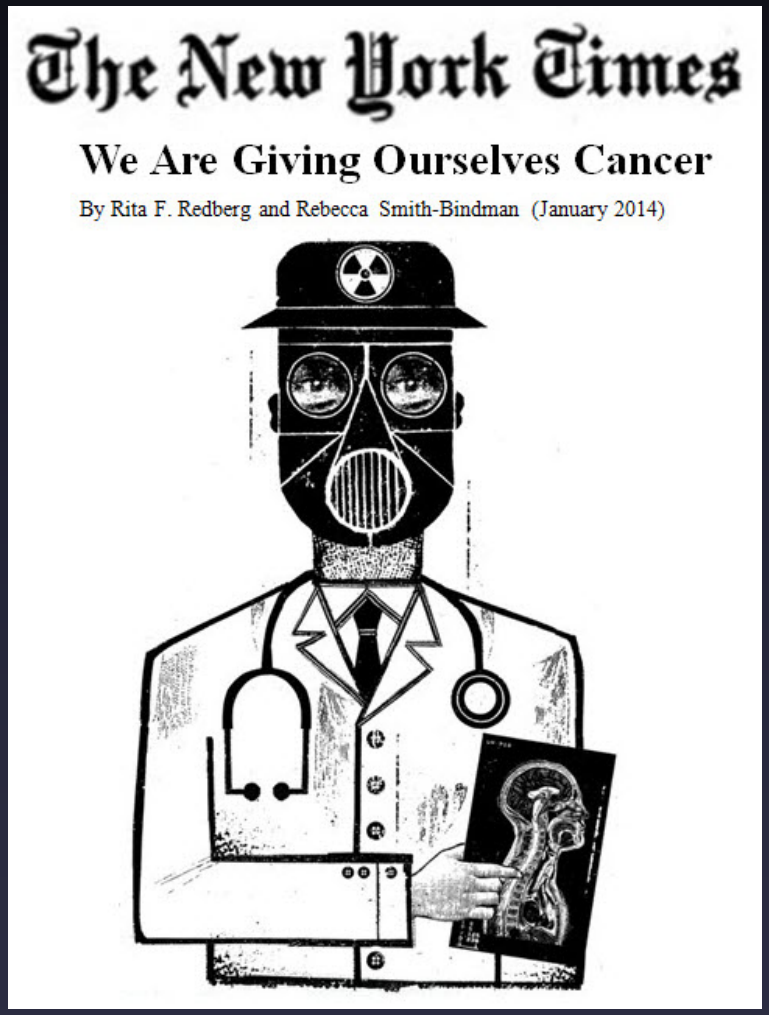
The New York Times

We Are Giving Ourselves Cancer

By Rita F. Redberg and Rebecca Smith-Bindman (January 2014)

"…. a reasonable estimate of excess lifetime cancers would be in the hundreds of thousands. According to our calculations, unless we change our current practices, 3 to 5 percent of all future cancers may result from exposure to medical imaging."

Dose Reduction at CT

- Prudent given perception of risk → ALARA
- Ongoing interaction between radiologists, physicists, and technologists (& referring docs)
- Beyond subjective & objective measures of image quality, we must maintain diagnostic performance (and confidence)
- Need to take patient population and specific study indication into consideration

IMAGE WISELY®
Radiation Safety in Adult Medical Imaging

Methods for Reducing Dose at CT

- Limit to clinically indicated studies
- Consider alternative imaging tests (US or MR)
- Limit scan coverage
- Tube current modulation
- Decrease kV setting
- Beam-shaping filters
- Z-axis collimators
- View in thicker slices
- Iterative reconstruction algorithms

Clinical Studies Employing IR

- Simple literature search yields >10,000 articles
- Mix of technical and clinical papers
- Of the clinical papers:
  - The vast majority report on dose reduction and various improvements (subjective and/or objective) in image quality, noise, etc, but very few:
  - 1) Compare standard & low dose from same exam
  - 2) Report on diagnostic performance and confidence
    - At AJR, I won't consider low-dose papers w/out this

UW Ultra-Low-Dose Body CT Trial

- Prospective trial (NIH NCI R01-CA169331)
  - Principal Investigators: Chen & Pickhardt
- IRB approved (recruitment ongoing)
  - Signed informed patient consent obtained
  - >200 patient studies performed to date
- Studies performed GE Discovery CT750 HD

UW Ultra-Low-Dose Body CT Trial

- Basic protocol:
  - "Ultra-low-dose" series obtained immediately after routine clinical series
  - Target dose reduction: 60-90% (indication specific)
  - Goal is to validate ultra-low-dose CT for clinical use
- Multiple sub-cohorts:
  - Unenhanced CT for urolithiasis
  - Unenhanced CT colonography

    Goal: sub-mSv
  - Contrast-enhanced CT (PV phase)
    - Low-contrast liver lesion detection in oncology pts
    - NHL surveillance

    Goal: sub-mSv

Perry J. Pickhardt[1]
Meghan G. Lubner[1]
David H. Kim[1]
Jie Tang[2]
Julie A. Ruma[1]
Alejandro Muñoz del Rio[1]
Guang-Hong Chen[1,2]

Abdominal CT With Model-Based Iterative Reconstruction (MBIR): Initial Results of a Prospective Trial Comparing Ultralow-Dose With Standard-Dose Imaging

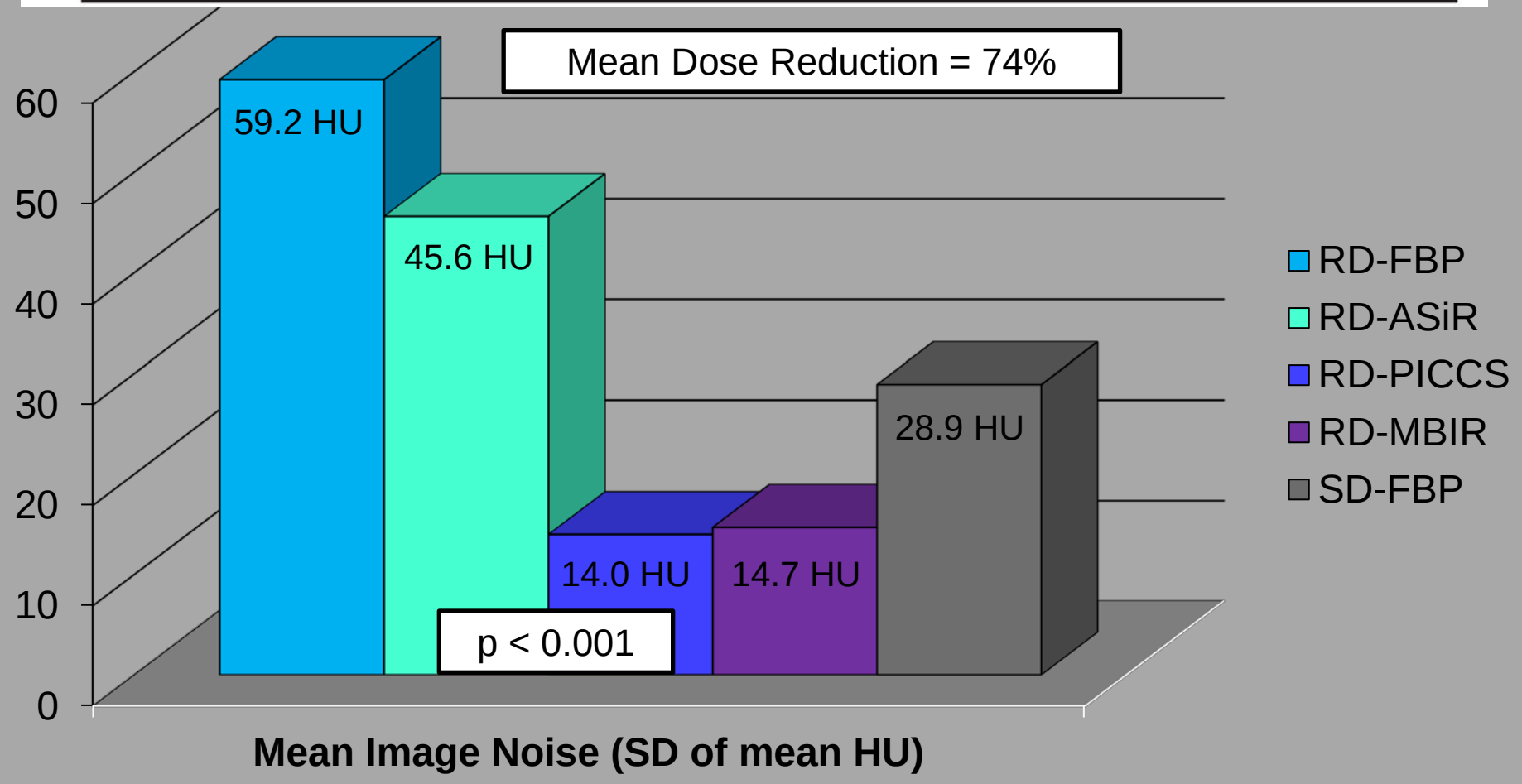

Perry J. Pickhardt[1]
Meghan G. Lubner[1]
David H. Kim[1]
Jie Tang[2]
Julie A. Ruma[1]
Alejandro Muñoz del Rio[1]
Guang-Hong Chen[1,2]

Abdominal CT With Model-Based Iterative Reconstruction (MBIR): Initial Results of a Prospective Trial Comparing Ultralow-Dose With Standard-Dose Imaging

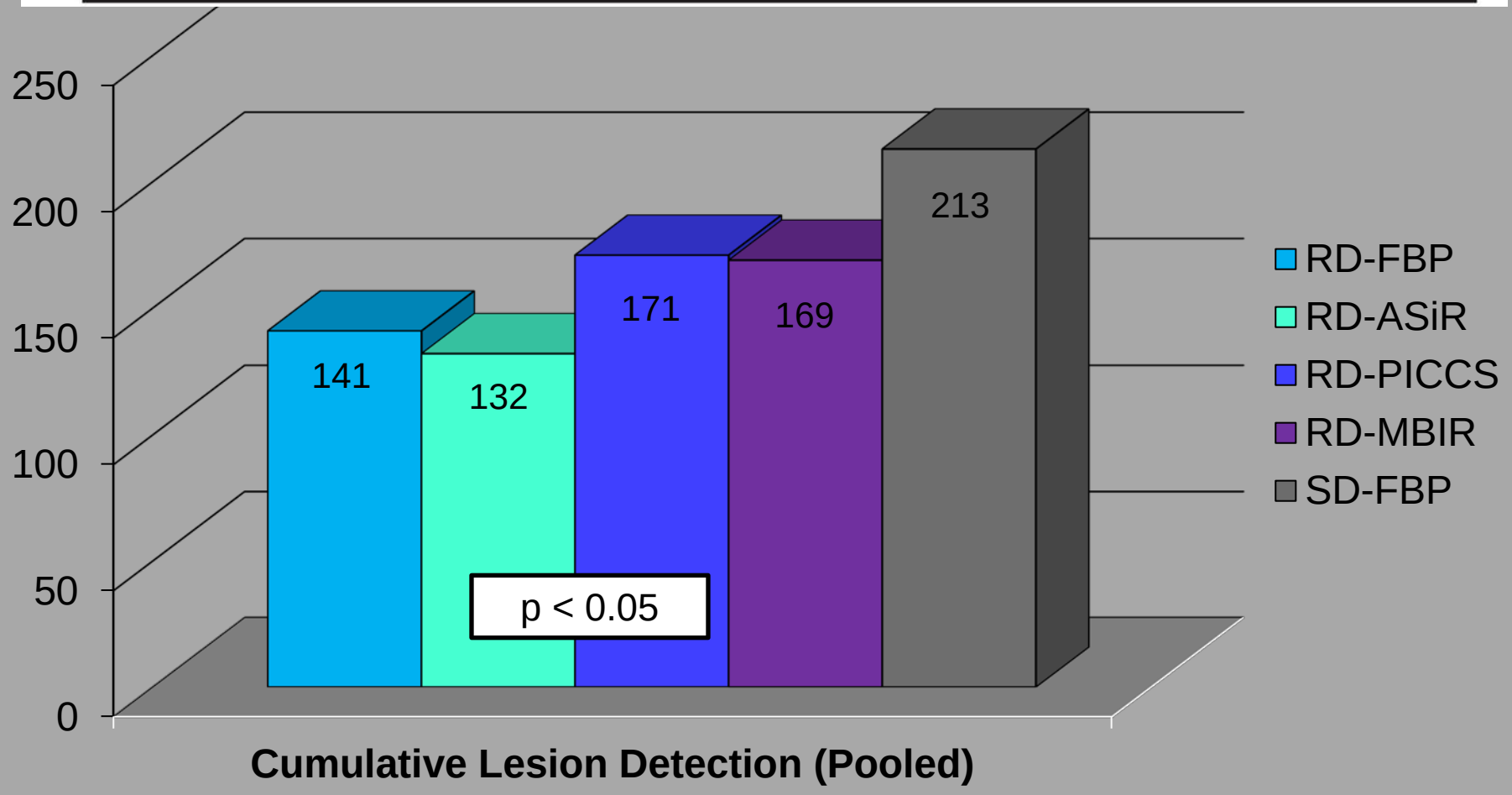

Perry J. Pickhardt[1]
Meghan G. Lubner[1]
David H. Kim[1]
Jie Tang[2]
Julie A. Ruma[1]
Alejandro Muñoz del Rio[1]
Guang-Hong Chen[1,2]

Abdominal CT With Model-Based Iterative Reconstruction (MBIR): Initial Results of a Prospective Trial Comparing Ultralow-Dose With Standard-Dose Imaging

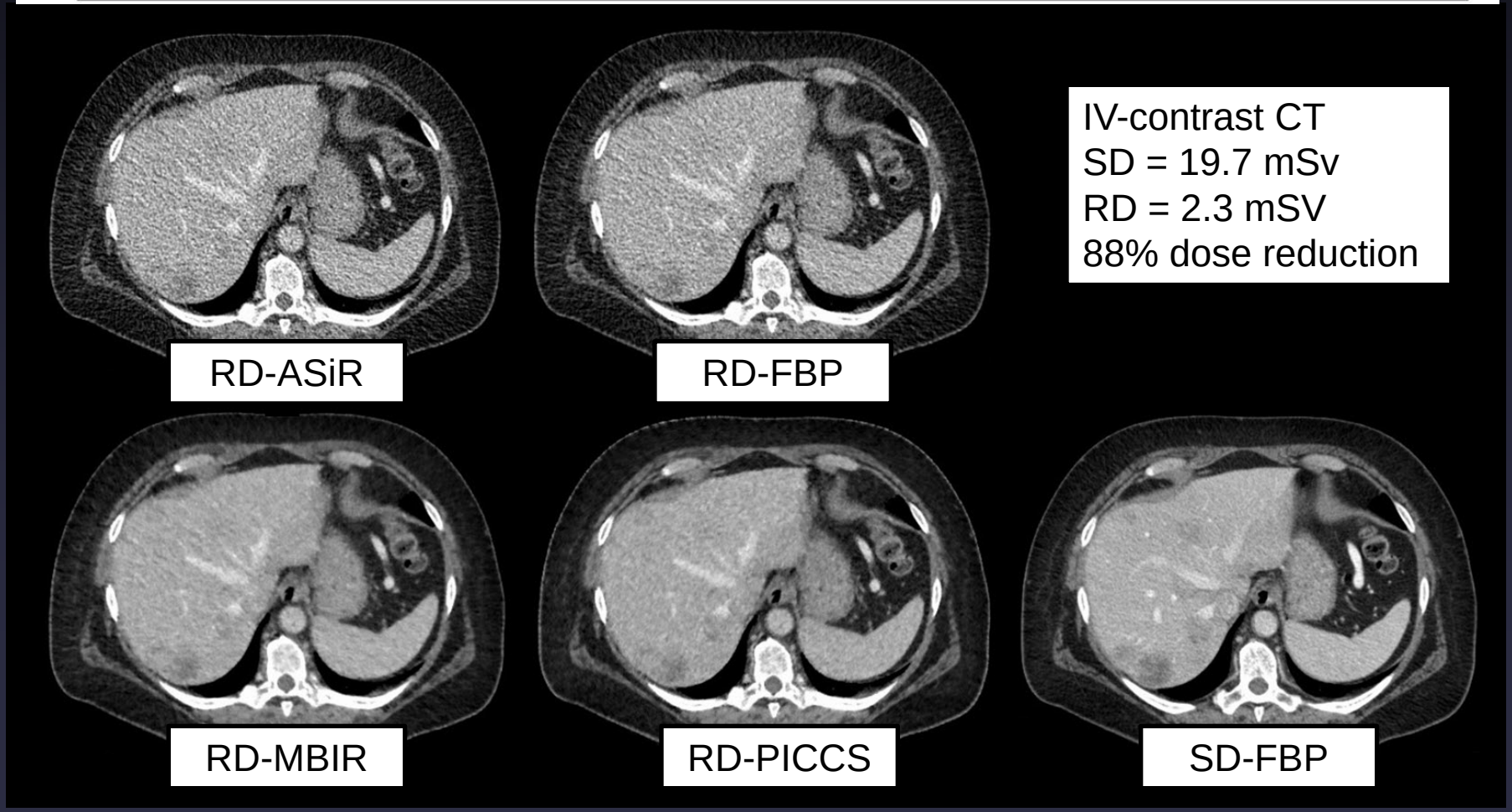

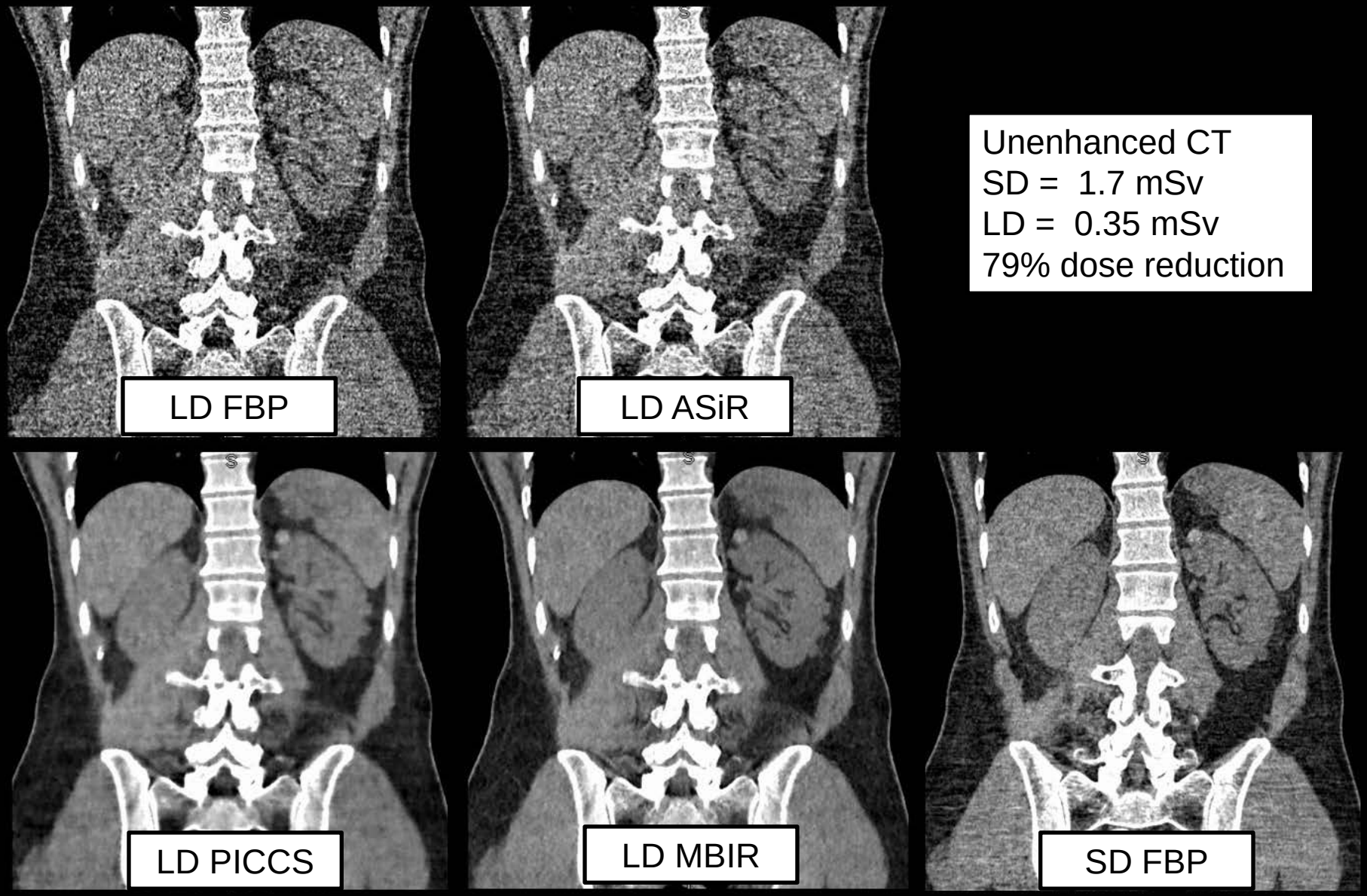

Unenhanced CT
SD = 1.7 mSv
LD = 0.35 mSv
79% dose reduction

Radiology

Reduced Image Noise at Low-Dose Multidetector CT of the Abdomen with Prior Image Constrained Compressed Sensing Algorithm[1]

Meghan G. Lubner, MD
Perry J. Pickhardt, MD
Jie Tang, PhD
Guang-Hong Chen, PhD

ABDOMINAL IMAGING

Prospective evaluation of prior image constrained compressed sensing (PICCS) algorithm in abdominal CT: a comparison of reduced dose with standard dose imaging

Meghan G. Lubner,[1] Perry J. Pickhardt,[1] David H. Kim,[1] Jie Tang,[2] Alejandro Munoz del Rio,[1] Guang-Hong Chen[1,2]

Prospective Trial of the Detection of Urolithiasis on Ultralow Dose (Sub mSv) Noncontrast Computerized Tomography: Direct Comparison against Routine Low Dose Reference Standard

B. Dustin Pooler, Meghan G. Lubner,* David H. Kim,† Eva M. Ryckman, Sri Sivalingam, Jie Tang, Stephen Y. Nakada, Guang-Hong Chen and Perry J. Pickhardt‡

From the Departments of Radiology (BDP, MGL, DHK, EMR, GHC, PJP), Urology (SS, SYN) and Medical Physics (JT, GHC), University of Wisconsin School of Medicine and Public Health, Madison, Wisconsin

THE JOURNAL of UROLOGY®

Sub-milliSievert (sub-mSv) CT colonography: a prospective comparison of image quality and polyp conspicuity at reduced-dose versus standard-dose imaging

Meghan G. Lubner · B. Dustin Pooler · Douglas R. Kitchin · Jie Tang · Ke Li · David H. Kim · Alejandro Munoz del Rio · Guang-Hong Chen · Perry J. Pickhardt

European Radiology
The official journal of the European Society of Radiology

Eur Radiol (2015) 25:2089–2102

Ultra-low (FBP)

Ultra-low (PICCS)

Effective Dose = 0.3 mSv

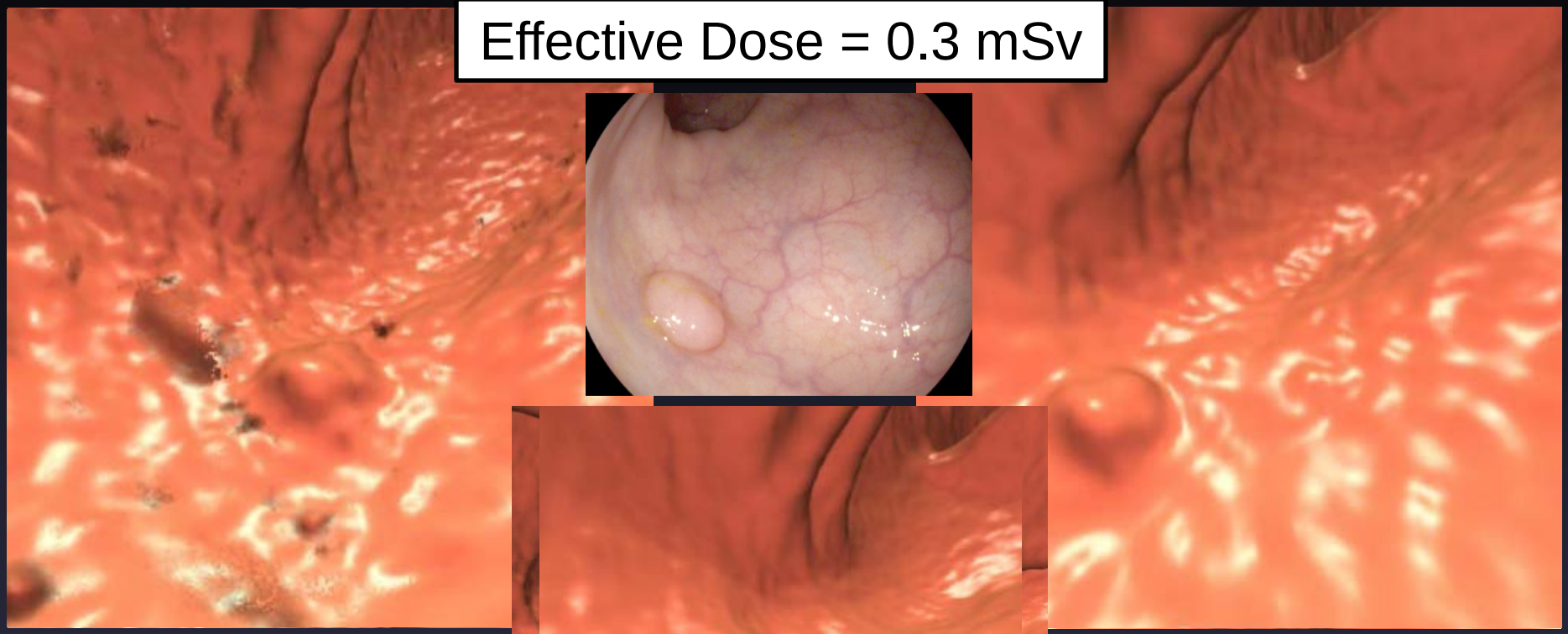

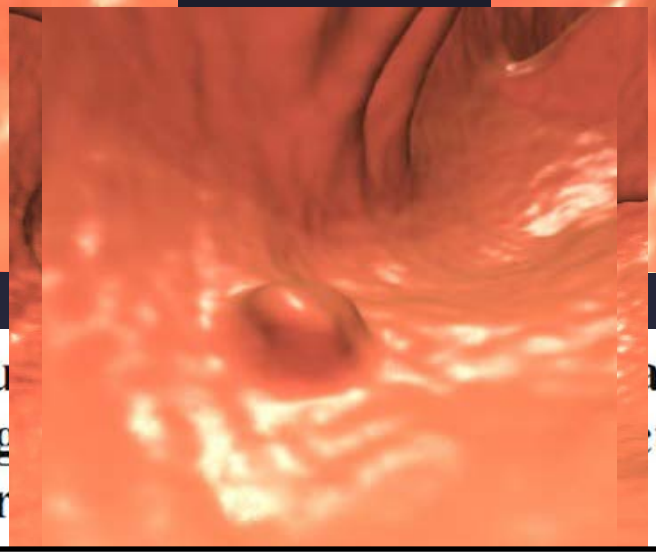

Sub-milliSievert (su
a prospective
comparison of imag
cuity
at reduced-dose ver

Meghan G. Lubner · B. Dusti
Douglas R. Kitchin · Jie Tang
Alejandro Munoz del Rio · G
Perry J. Pickhardt

Radiology
The official journal of the European Society of Radiology

–2102

Effective Dose = 2.7 mSv

Standard (FBP)

Prospective Trial of the Detection of Urolithiasis on Ultralow Dose (Sub mSv) Noncontrast Computerized Tomography: Direct Comparison against Routine Low Dose Reference Standard

B. Dustin Pooler, Meghan G. Lubner,* David H. Kim,† Eva M. Ryckman, Sri Sivalingam, Jie Tang, Stephen Y. Nakada, Guang-Hong Chen and Perry J. Pickhardt‡

From the Departments of Radiology (BDP, MGL, DHK, EMR, GHC, PJP), Urology (SS, SYN) and Medical Physics (JT, GHC), University of Wisconsin School of Medicine and Public Health, Madison, Wisconsin

THE JOURNAL of UROLOGY®

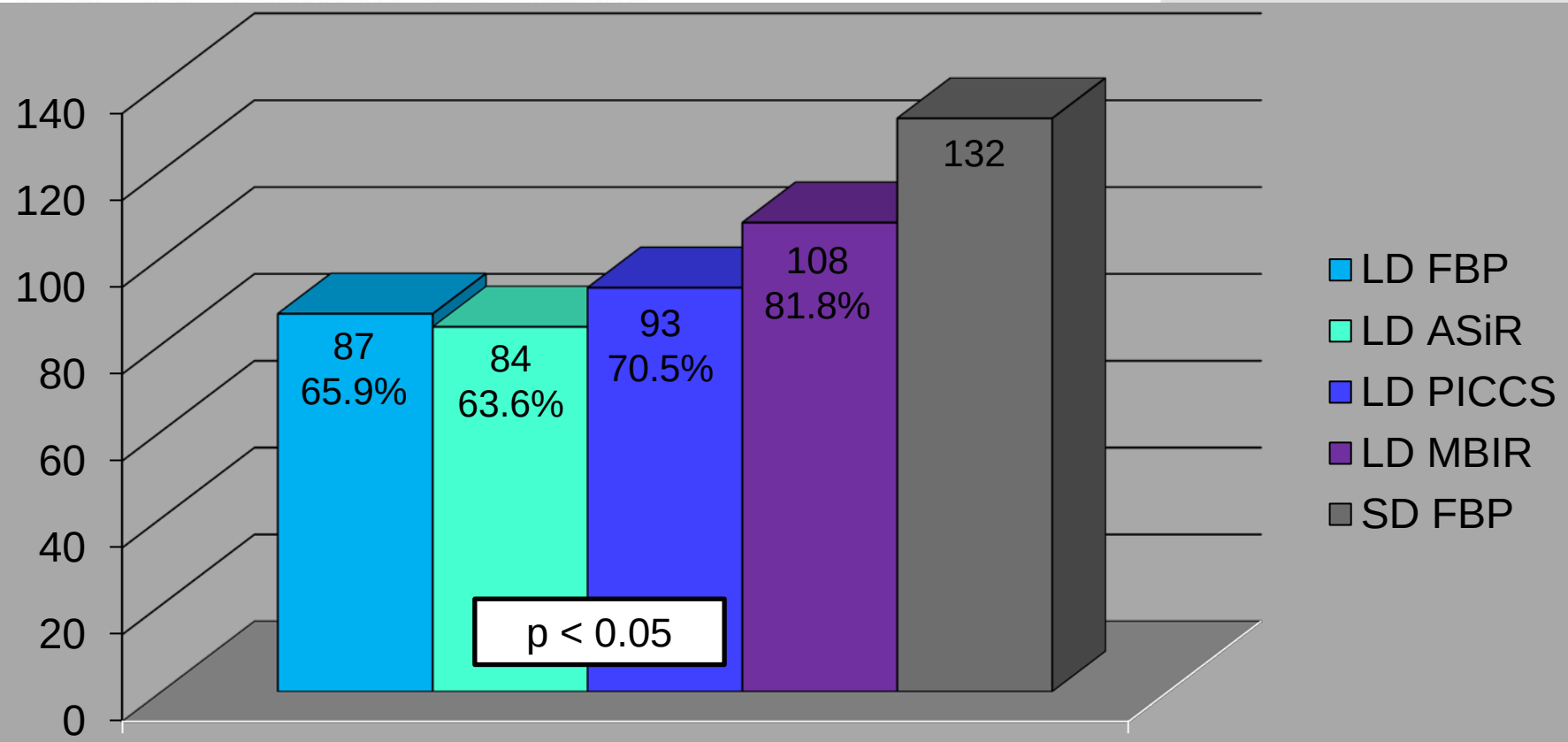

Total Prospective Stone Detection (Pooled)

Prospective Trial of the Detection of Urolithiasis on Ultralow Dose (Sub mSv) Noncontrast Computerized Tomography: Direct Comparison against Routine Low Dose Reference Standard

B. Dustin Pooler, Meghan G. Lubner,* David H. Kim,† Eva M. Ryckman, Sri Sivalingam, Jie Tang, Stephen Y. Nakada, Guang-Hong Chen and Perry J. Pickhardt‡

From the Departments of Radiology (BDP, MGL, DHK, EMR, GHC, PJP), Urology (SS, SYN) and Medical Physics (JT, GHC), University of Wisconsin School of Medicine and Public Health, Madison, Wisconsin

THE JOURNAL of UROLOGY®

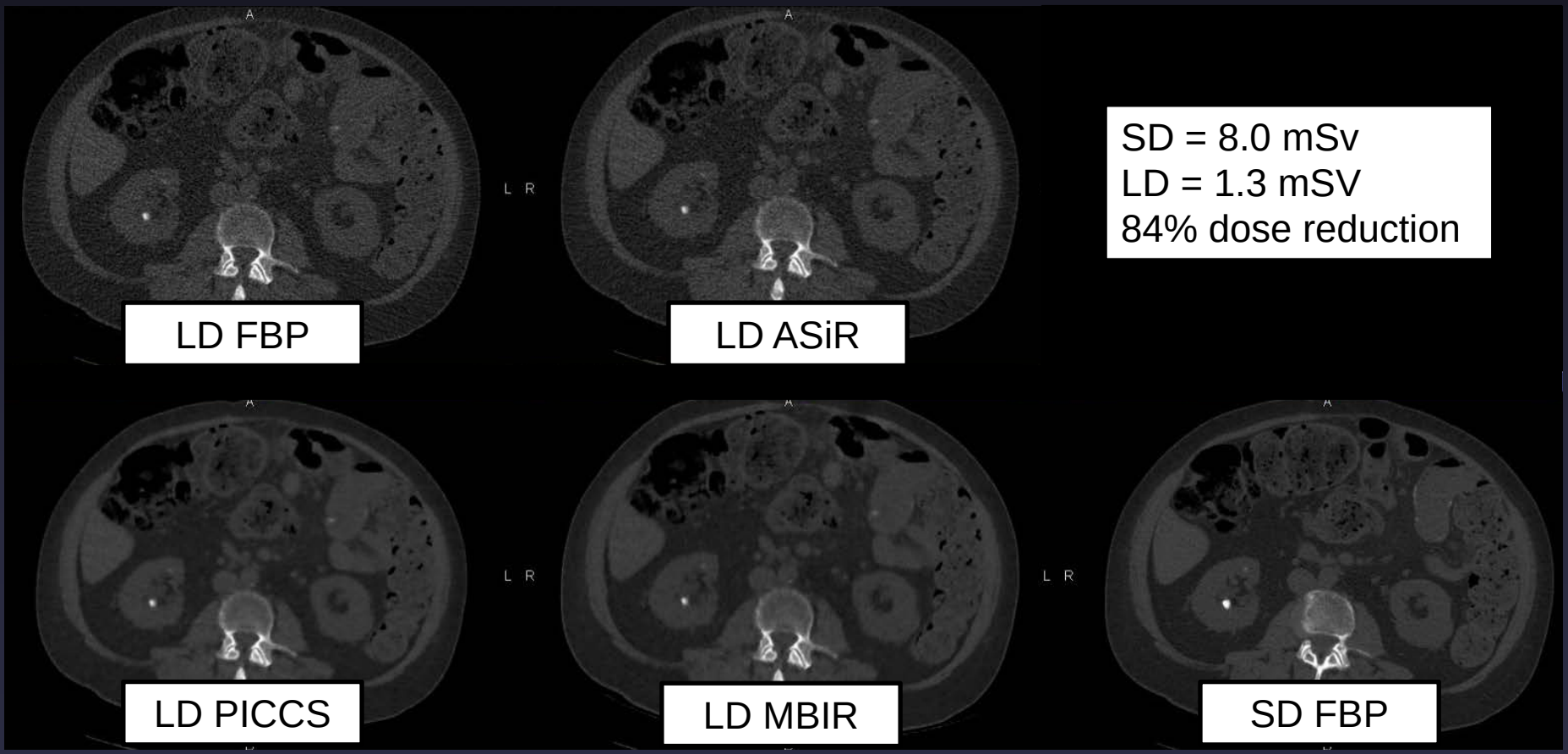

SD = 8.0 mSv
LD = 1.3 mSV
84% dose reduction

Prospective Trial of the Detection of Urolithiasis on Ultralow Dose (Sub mSv) Noncontrast Computerized Tomography: Direct Comparison against Routine Low Dose Reference Standard

B. Dustin Pooler, Meghan G. Lubner,* David H. Kim,† Eva M. Ryckman, Sri Sivalingam, Jie Tang, Stephen Y. Nakada, Guang-Hong Chen and Perry J. Pickhardt‡

From the Departments of Radiology (BDP, MGL, DHK, EMR, GHC, PJP), Urology (SS, SYN) and Medical Physics (JT, GHC), University of Wisconsin School of Medicine and Public Health, Madison, Wisconsin

THE JOURNAL of UROLOGY®

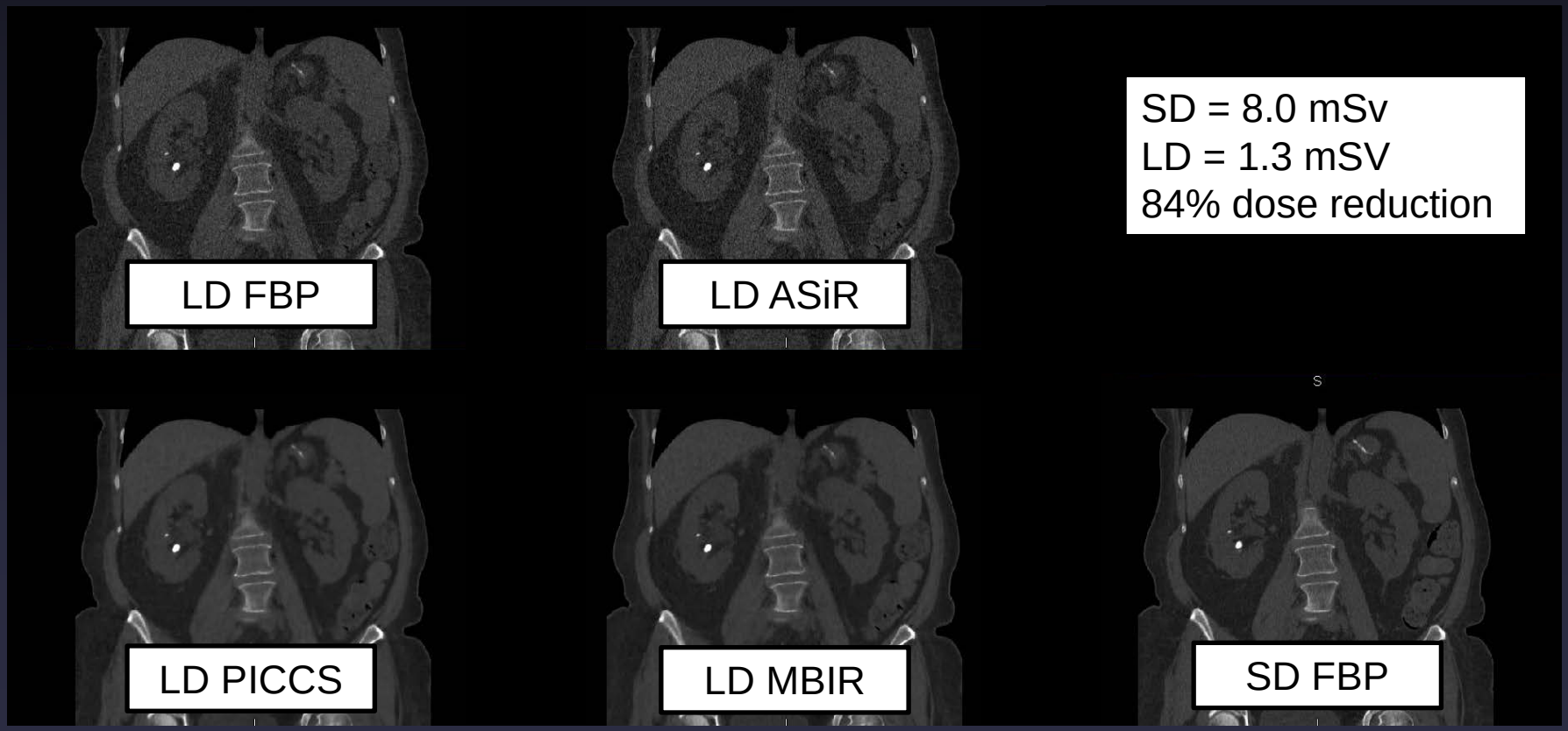

Lymphoma Surveillance

Standard

Low-Dose

Goal: 90% dose reduction; Chest <1 mSv; A/P ~1 mSv

Lymphoma Surveillance

Standard

Low-Dose

Goal: 90% dose reduction; Chest <1 mSv; A/P ~1 mSv

Lymphoma Surveillance

A:	12-11-14 12:23	CT	CT CHEST ABDOMEN PELVIS W IV CONTRAST, UWMF21389645	3092 Images
R1(CT1):	12-11-14 12:23	CT	Source Images, SUWMF21389645	1155 Images
R2(CT2):	05-29-14 12:31	CT	CT CHEST ABDOMEN PELVIS W IV CONTRAST, UWHC21103845	2845 Images
	05-29-14 11:55	CT	CT NECK W CT/ PET LIMITED, UWHC21065836	314 Images
	12-23-13 12:49	CT	CT CHEST ABDOMEN PELVIS W IV CONTRAST, UWHC20889587	2735 Images
	12-23-13 12:12	CT	CT NECK W CT/ PET LIMITED, UWHC20824479	402 Images
	06-28-13 12:40	CT	CT CHEST ABDOMEN PELVIS W IV CONTRAST, UWHC20517937	2651 Images
	06-28-13 11:59	CT	CT NECK W CT/ PET LIMITED, UWHC20517939	402 Images
	01-10-13 08:42	CT	CT NECK SOFT TISSUE W CONTRAST MER, MER238337	1247 Images
	01-10-13 08:42	CT	CT CHEST ABDOMEN PELVIS W CONTRAST MER, MER238339	1434 Images
	06-19-12 09:30	CT	CT CHEST ABDOMEN PELVIS W CONTRAST MER, MER199866	2129 Images
	06-18-12 09:17	CT	CT NECK W CT/ PET LIMITED, UWHC20103225	402 Images
	03-21-12 10:47	CT	CT CHEST ABDOMEN PELVIS W CONTRAST MER, MER181420	937 Images
	03-21-12 10:47	CT	CT NECK SOFT TISSUE W CONTRAST MER, MER181421	1070 Images
	12-21-11 11:50	CT	CT NECK SOFT TISSUE W CONTRAST MER, MER165733	1011 Images
	12-05-11 14:08	CT	CT THORAX W CONTRAST MER, MER162124	897 Images
	12-01-11 14:29	CT	CT BIOPSY ABDOMEN RETROPERITONEAL MER, MER161684	103 Images
	11-30-11 13:04	CT	CT ABDOMEN UPPER/PELVIS WC MER, MER161548	446 Images

All Studies

12-11-14 12:23	CT	CT CHEST ABDOMEN PELVIS W IV CONTRAST, UWMF21389645	3092 Images
12-11-14 12:23	CT	Source Images, SUWMF21389645	1155 Images
10-10-14 15:16	US	US NECK SOFT TISSUES, UWMF21298162	24 Images
05-29-14 12:31	CT	CT CHEST ABDOMEN PELVIS W IV CONTRAST, UWHC21103845	2845 Images
05-29-14 11:55	PT	PET CT SKULL BASE TO THIGH, UWHC21065835	1693 Images
05-29-14 11:55	CT	CT NECK W CT/ PET LIMITED, UWHC21065836	314 Images
03-26-14 15:52	US	US TRANSVAGINAL _PELVIS, UWMF21009391	41 Images
12-23-13 14:14	MG	MAMMOGRAM DIGITAL SCREENING BILATERAL, UWMF20855867	6 Images
12-23-13 12:49	CT	CT CHEST ABDOMEN PELVIS W IV CONTRAST, UWHC20889587	2735 Images
12-23-13 12:12	CT	CT NECK W CT/ PET LIMITED, UWHC20824479	402 Images
12-23-13 12:12	PT	PET CT SKULL BASE TO THIGH, UWHC20889588	1807 Images
06-28-13 12:40	CT	CT CHEST ABDOMEN PELVIS W IV CONTRAST, UWHC20517937	2651 Images
06-28-13 11:59	PT	PET CT SKULL BASE TO THIGH, UWHC20517938	1814 Images
06-28-13 11:59	CT	CT NECK W CT/ PET LIMITED, UWHC20517939	402 Images
01-10-13 08:42	CT	CT NECK SOFT TISSUE W CONTRAST MER, MER238337	1247 Images
01-10-13 08:42	CT	CT CHEST ABDOMEN PELVIS W CONTRAST MER, MER238339	1434 Images
10-16-12 10:43	MG	MAMMOGRAM DIGITAL SCREENING BILATERAL, UWMF20296448	5 Images
06-19-12 09:30	CT	CT CHEST ABDOMEN PELVIS W CONTRAST MER, MER199866	2129 Images
06-18-12 09:17	CT	CT NECK W CT/ PET LIMITED, UWHC20103225	402 Images
06-18-12 09:17	PT	PET CT SKULL BASE TO THIGH, UWHC20103226	1635 Images
03-21-12 10:47	CT	CT CHEST ABDOMEN PELVIS W CONTRAST MER, MER181420	937 Images
03-21-12 10:47	CT	CT NECK SOFT TISSUE W CONTRAST MER, MER181421	1070 Images
03-19-12 15:36	CT	CT NECK W CT/ PET LIMITED, 11225230	0 Images
03-19-12 10:46	PT	PET CT SKULL BASE TO THIGH, 11225231	1630 Images
12-22-11 20:57	CT	CT NECK LIMITED WITH CT/PET, 11137008	0 Images
12-22-11 10:53	PT	PET/CT SKULL BASE TO THIGH, 11137009	1654 Images
12-21-11 11:50	CT	CT NECK SOFT TISSUE W CONTRAST MER, MER165733	1011 Images
12-06-11 11:05	CR	XR CHEST SINGLE VIEW MER, MER162871	2 Images
12-05-11 14:08	CT	CT THORAX W CONTRAST MER, MER162124	897 Images
12-05-11 11:33	MR	MRI BRAIN W WO CONTRAST MER, MER162130	556 Images
12-01-11 14:29	CT	CT BIOPSY ABDOMEN RETROPERITONEAL MER, MER161684	103 Images
11-30-11 13:04	CT	CT ABDOMEN UPPER/PELVIS WC MER, MER161548	446 Images
12-13-10 16:14	MG	MAMMOGRAM SCREENING W CAD, UWMF588936	4 Images
07-30-08 19:36	US	US DUPLEX EXT VEINS UNILATERAL, 23068044	31 Images
06-25-08 16:43	MG	MAMMO SCRN, UWMF252449	4 Images
05-07-07 13:17	MG	MAMMO SCRN, UWMF221023	4 Images

Low-contrast Lesion Detection

- A more challenging but critical CT task

AJR FOCUS ON:

Mark E. Baker[1,2]
Frank Dong[1]
Andrew Primak[3]
Nancy A. Obuchowski[4]
David Einstein[1]
Namita Gandhi[1]
Brian R. Herts[1]
Andrei Purysko[1]
Erick Remer[1]
Neil Vachani[1]

Contrast-to-Noise Ratio and Low-Contrast Object Resolution on Full- and Low-Dose MDCT: SAFIRE Versus Filtered Back Projection in a Low-Contrast Object Phantom and in the Liver

Radiology

Cynthia H. McCollough, PhD
Lifeng Yu, PhD
James M. Kofler, PhD
Shuai Leng, PhD
Yi Zhang, PhD
Zhoubo Li, MS
Rickey E. Carter, PhD

Degradation of CT Low-Contrast Spatial Resolution Due to the Use of Iterative Reconstruction and Reduced Dose Levels[1]

MEDICAL PHYSICS

Low-contrast Lesion Detection

- A more challenging but critical CT task

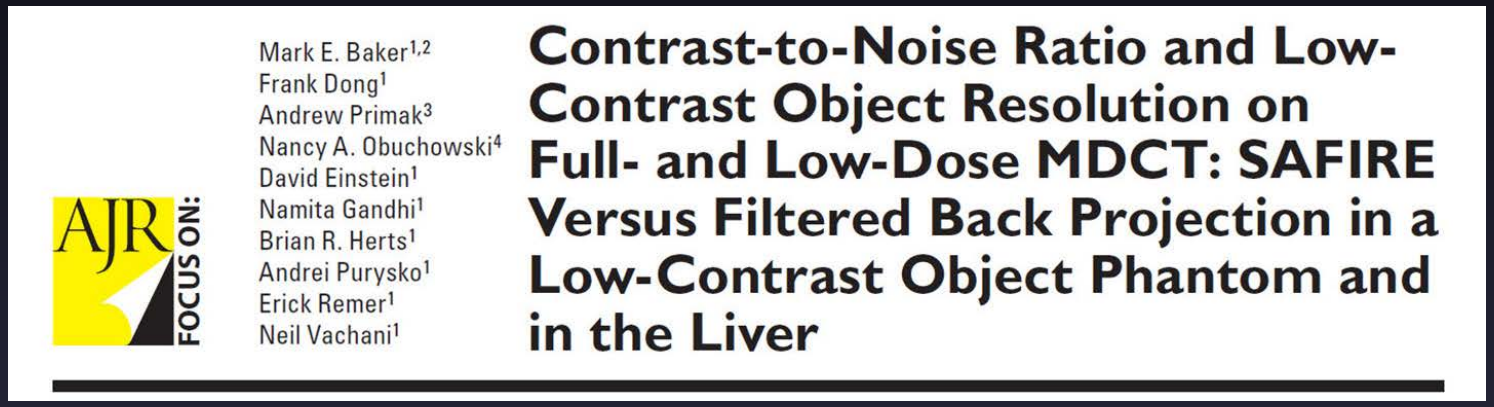



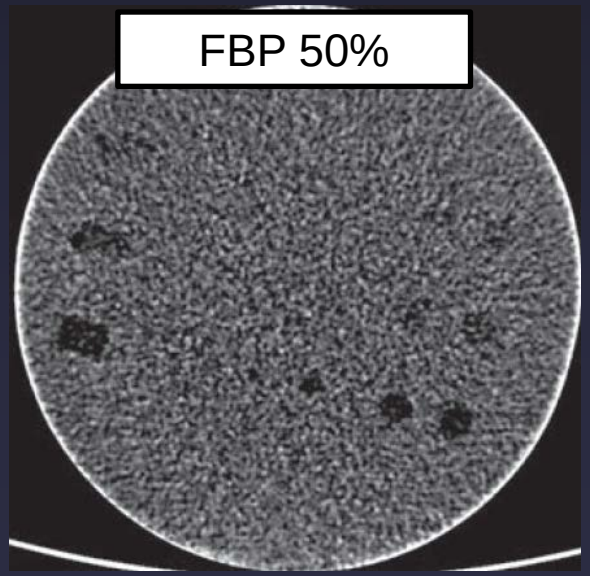

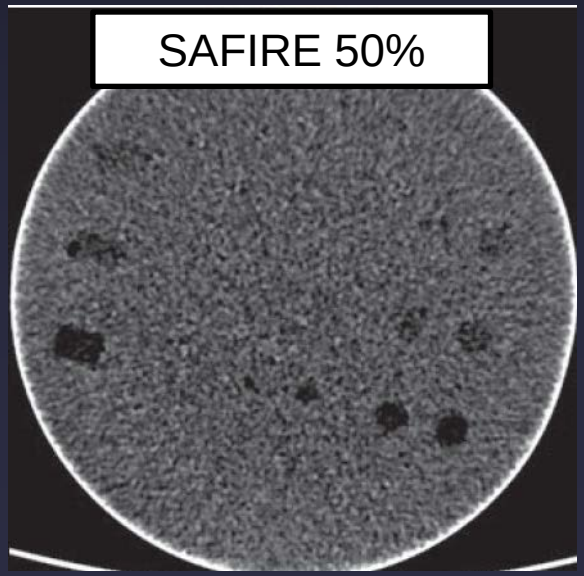

Low-contrast Liver Lesion Detection

COMPUTED TOMOGRAPHY

European Radiology
The official journal of the European Society of Radiology

Prospective Evaluation of Reduced Dose Computed Tomography for the Detection of Low-Contrast Liver Lesions: Direct Comparison with Concurrent Standard Dose Imaging

B. Dustin Pooler[1] · Meghan G. Lubner[1] · David H. Kim[1] · Oliver T. Chen[1] · Ke Li[1,2] · Guang-Hong Chen[1,2] · Perry J. Pickhardt[1,3]

- Patient cohort:
  - 70 adults with non-liver primary malignancy
  - Mean age, 59.4 ± 12.8 yrs; 31 men, 39 women
  - Mean BMI, 27.7 ± 5.2 kg/m^2

Low-contrast Liver Lesion Detection

COMPUTED TOMOGRAPHY

European Radiology
The official journal of the European Society of Radiology

Prospective Evaluation of Reduced Dose Computed Tomography for the Detection of Low-Contrast Liver Lesions: Direct Comparison with Concurrent Standard Dose Imaging

B. Dustin Pooler[1] · Meghan G. Lubner[1] · David H. Kim[1] · Oliver T. Chen[1] · Ke Li[1,2] · Guang-Hong Chen[1,2] · Perry J. Pickhardt[1,3]

- Patient cohort:
  - Primary tumors:
    - Colorectal (n=18), Pancreatic (n=14), Neuroendocrine (n=9), Breast (n=9), Lung (n=4), Esophagus (n=3), GIST (n=3), Other (n=10)

Low-contrast Liver Lesion Detection

COMPUTED TOMOGRAPHY

European Radiology
The official journal of the European Society of Radiology

Prospective Evaluation of Reduced Dose Computed Tomography for the Detection of Low-Contrast Liver Lesions: Direct Comparison with Concurrent Standard Dose Imaging

B. Dustin Pooler[1] · Meghan G. Lubner[1] · David H. Kim[1] · Oliver T. Chen[1] · Ke Li[1,2] · Guang-Hong Chen[1,2] · Perry J. Pickhardt[1,3]

- Patient cohort:
  - SD CT A/P with IV contrast in PVP for mestatic survey
    - Followed by RD scan in same breath hold (60-70% reduction)
    - SD-FBP compared with RD-FBP, RD-ASiR, RD-MBIR (Veo)
    - Transverse (axial) and coronal reconstructions

Low-contrast Liver Lesion Detection

- CT interpretation:
  - All series randomized and reviewed in isolation
    - SD and RD series
    - >1 week washout between sessions
  - 3 readers blinded to all clinical data (& other CT's)
    - Radiology attending, fellow, and resident
  - Size, location, density recorded for all lesions ≥4 mm
    - 5 most concerning lesions recorded
  - Diagnostic performance per-lesion and per-patient

Low-contrast Liver Lesion Detection

- CT interpretation:
  - 5-point score for likelihood of malignancy
    - 1 = definitely benign
    - 2 = likely benign
    - 3 = indeterminate
    - 4 = likely malignant
    - 5 = definitely malignant
  - 3-point score for diagnostic confidence
    - 1 = low confidence
    - 2 = moderate confidence
    - 3 = high confidence

Low-contrast Liver Lesion Detection

- Reference standard (ground truth):
  - All series reviewed in concert with relevant prior and subsequent imaging (CT, MR, PET/CT, etc) and clinical data by 2 abdominal radiologists
    - Mean of 5.3 CT scans over 2.1 years prior to index study
    - Mean of 4.3 CT scans over 1.6 years following index study
  - Each liver lesion classified
- Mean effective dose:
  - Standard dose series = 5.8 ± 4.0 mSv
  - Reduced dose series = 2.0 ± 1.4 mSv
  - Mean dose reduction = 64%

Low-contrast Liver Lesion Detection

	SD-FBP	RD-FBP	RD-ASIR	RD-MBIR
Sensitivity	0.91 [0.84-0.99]	0.79 [0.68-0.90]	0.84 [0.75-0.94]	0.84 [0.75-0.94]
Specificity	0.78 [0.71-0.84]	0.75 [0.68-0.82]	0.75 [0.68-0.82]	0.68 [0.61-0.75]
PPV	0.60 [0.50-0.71]	0.54 [0.43-0.65]	0.56 [0.45-0.66]	0.49 [0.40-0.59]
NPV	0.96 [0.93-0.99]	0.91 [0.85-0.95]	0.93 [0.88-0.97]	0.92 [0.87-0.97]
Accuracy	0.81 [0.76-0.87]	0.76 [0.70-0.82]	0.78 [0.72-0.83]	0.72 [0.66-0.78]

Low-contrast Liver Lesion Detection

	SD-FBP	RD-FBP	RD-ASIR	RD-MBIR
Sensitivity	91%	79%	84%	84%
Specificity	78%	75%	75%	68%
PPV	60%	54%	56%	49%
NPV	96%	91%	93%	92%
Accuracy	81%	76%	78%	72%

Low-contrast Liver Lesion Detection

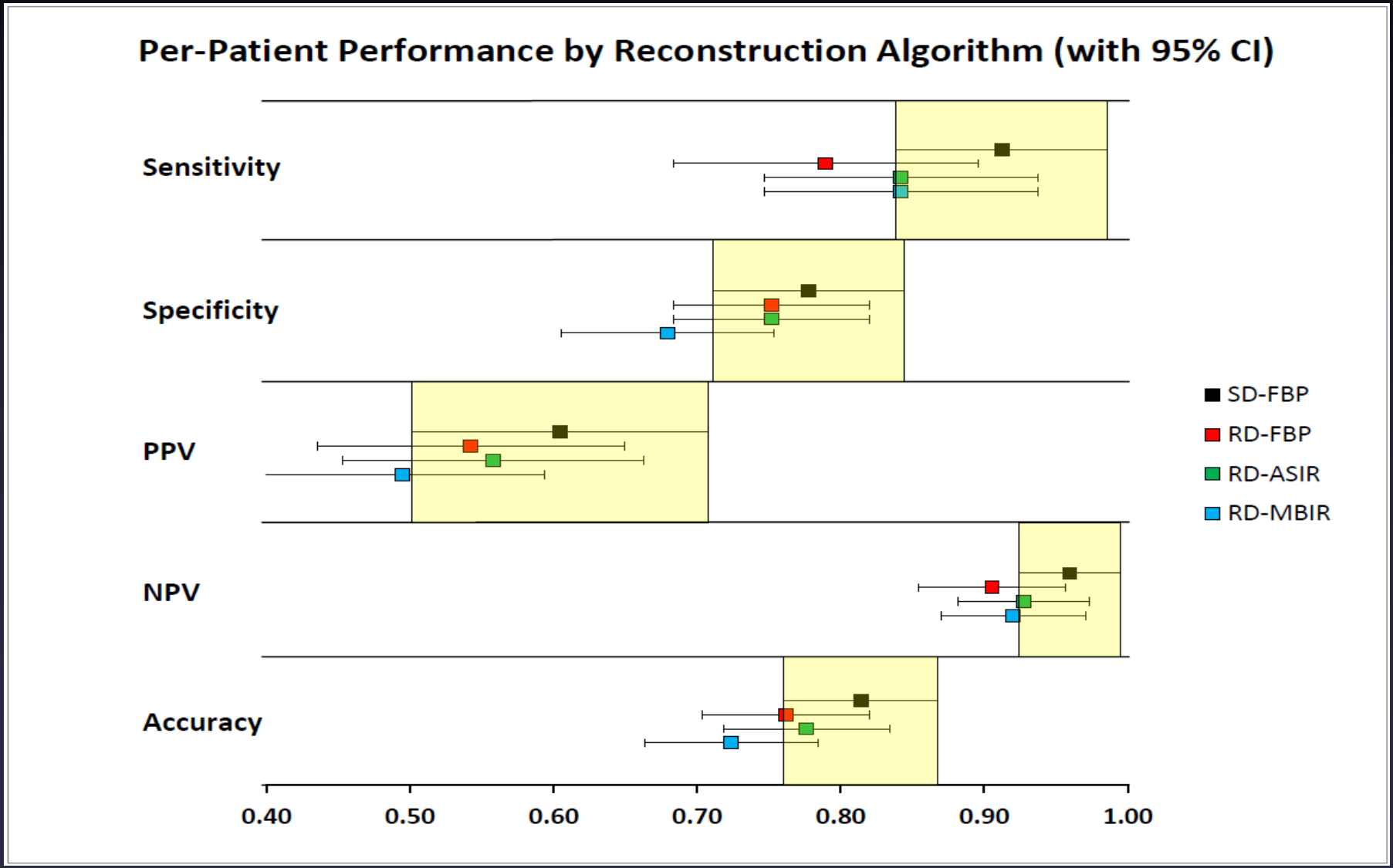

Low-contrast Liver Lesion Detection

	SD-FBP	RD-FBP	RD-ASIR	RD-MBIR
True Positive Malignant	2.89	2.77 $p=0.016$	2.79 $p=0.038$	2.87 $p=0.596$
True Positive Benign	2.96	2.96 $p=0.922$	2.95 $P=0.711$	2.91 $p=0.215$
False Positive	2.43	1.64 $p=0.009$	2.00 $p=0.141$	1.69 $p<0.001$
False Negative	3.00	2.33 $p=0.495$	2.50 $p=0.423$	3.00 $p=1.000$
True Negative	2.70	1.98 $p<0.001$	1.98 $p<0.001$	1.62 $p<0.001$

Low-contrast Liver Lesion Detection

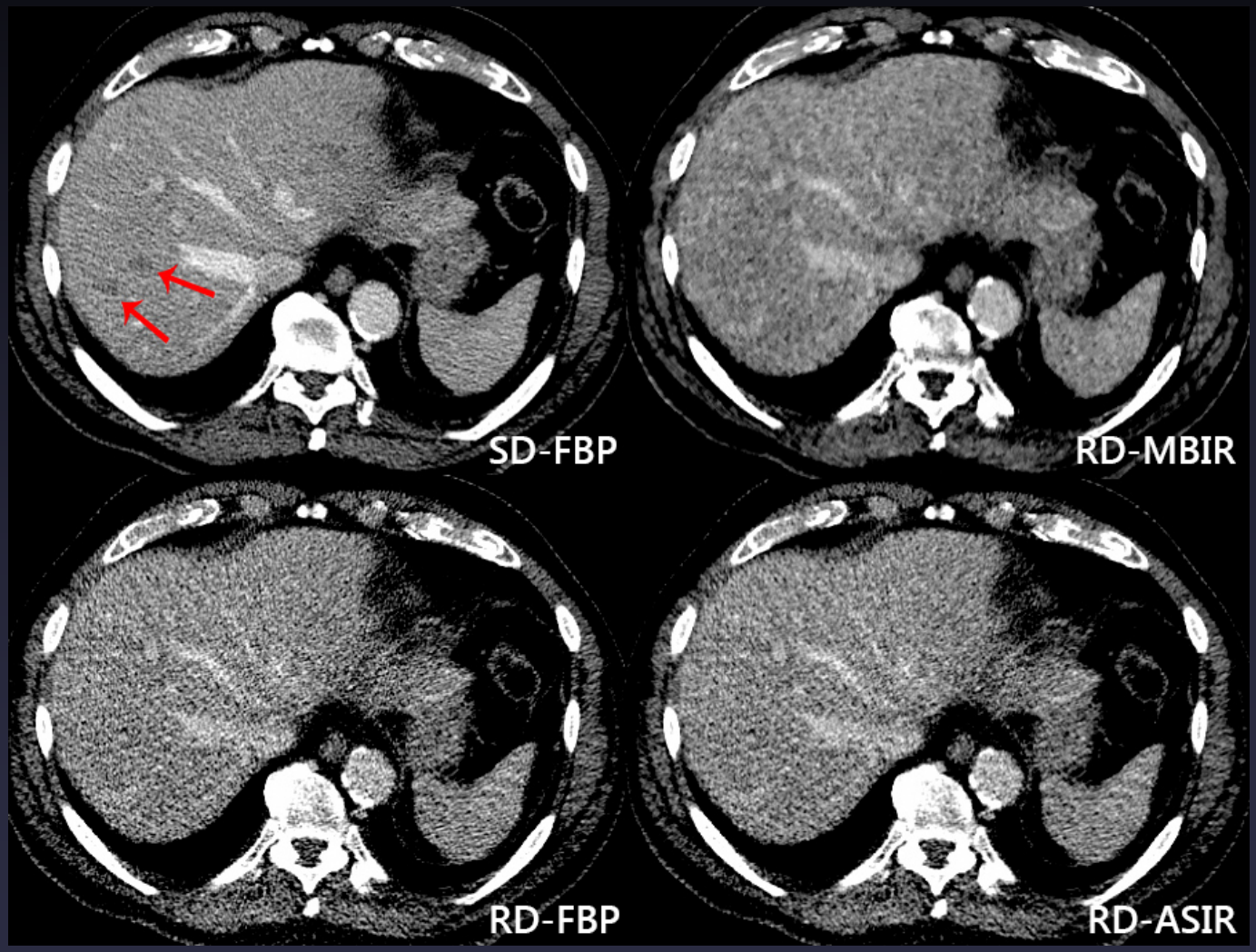

False Negative at RD

Low-contrast Liver Lesion Detection

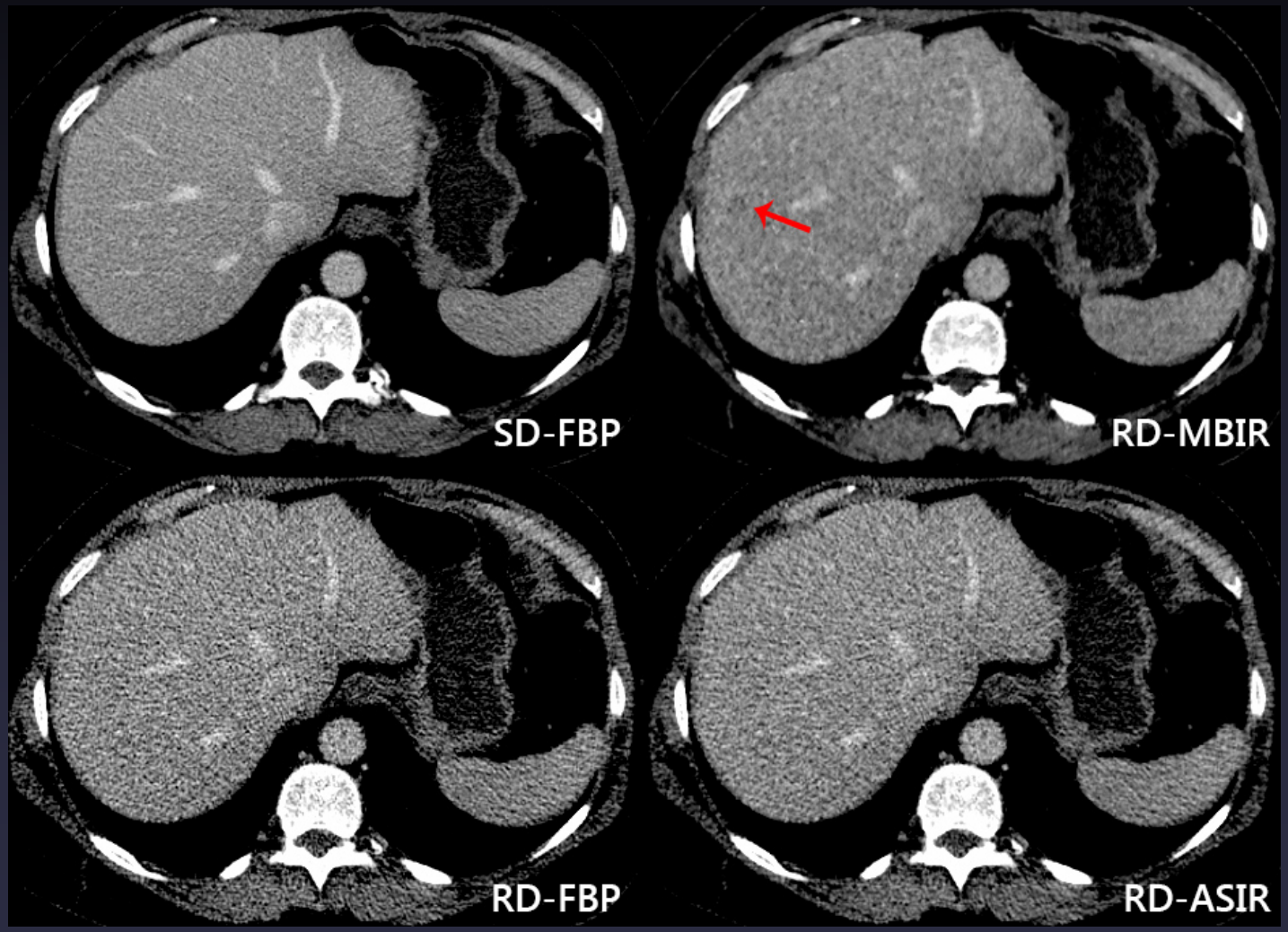

False Positive at RD-MBIR

Clinical Dose Initiatives at UW

- "Master Protocol" concept
  - Partnership with GE Healthcare
  - Clinically-validated and dose-optimized protocols

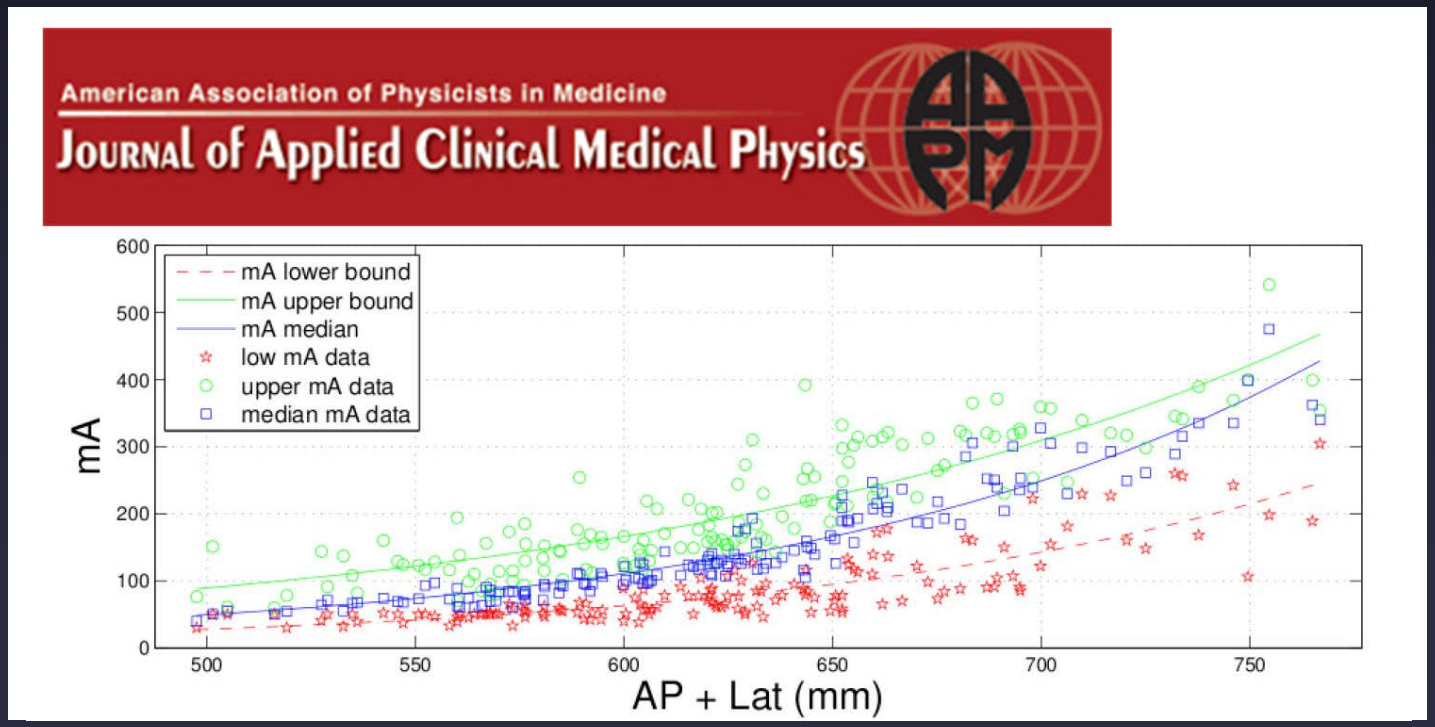

Clinical Dose Initiatives at UW

- Auto-QA system

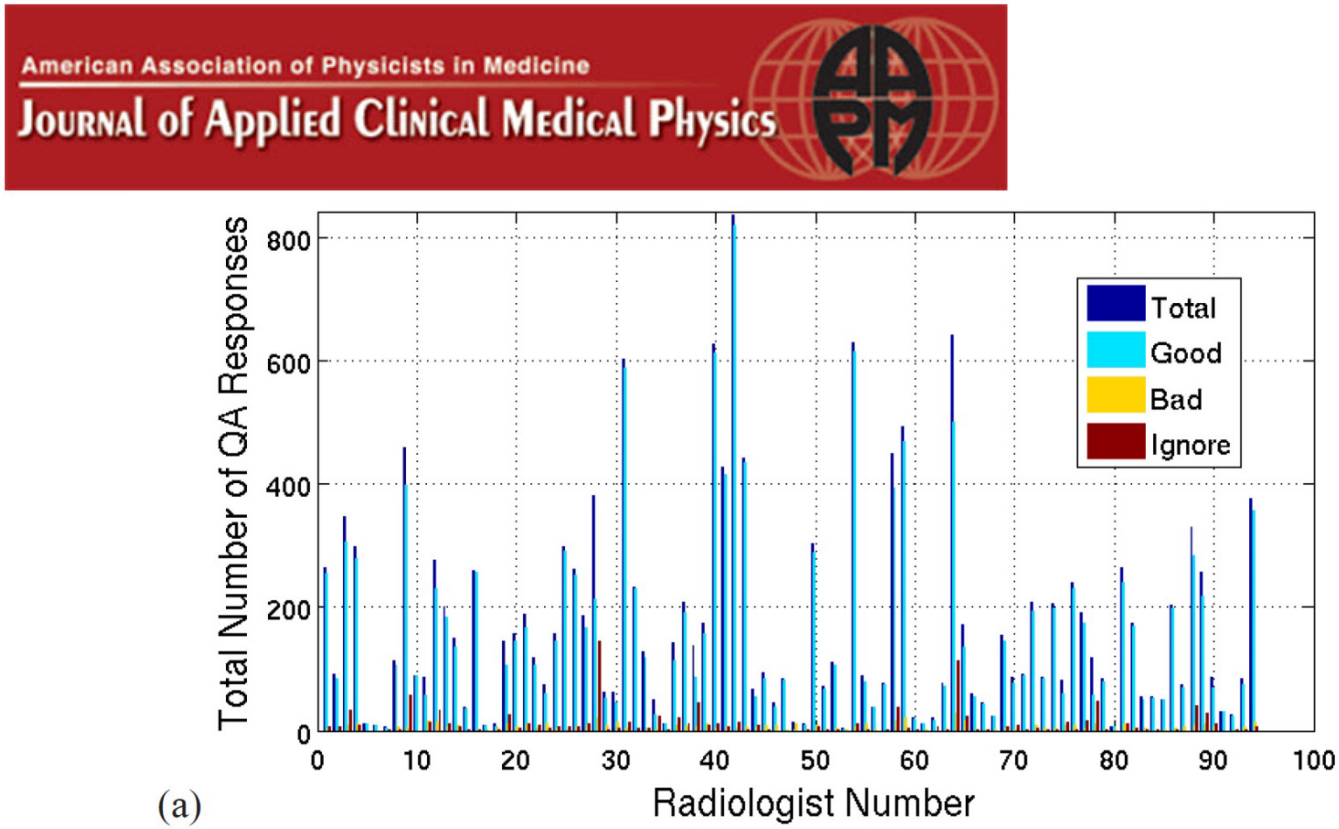

Conclusions

- Aggressive dose reduction at CT is achievable
  - Especially for certain tasks (CTC, urolithiasis, NHL f/u)
  - Sub-mSv scanning possible
- Caution warranted for low-contrast lesion search
  - Diagnostic performance can fall off rapidly at low dose
- Critical to tailor dose reduction goals to both the clinical task and the patient cohort
  - ALARA concept remains a central tenet
  - Critical to maintain diagnostic ability as treatment decisions greatly outweigh the unproven theoretical harm related to low-level radiation
  - Iterative QA can effectively inform CT protocols

Thank You