Physics and Clinical Perspectives On Tomosynthesis: 1) Physics and Technology of Tomosynthesis

Andrew D. A. Maidment, Ph.D.
University of Pennsylvania
Department of Radiology

Acknowledgements of Support

- Research support from the Komen Foundation, DOD, NIH, BWF, Barco NV, Hologic Inc, and Analogic Inc.
- Dr. Maidment is a scientific advisor to and shareholder of Real Time Tomography, LLC.
- Dr. Maidment is a founder and shareholder of Daimroc, LLC.

FDA Statement

- This presentation will include off-label uses and applications and devices not yet approved for human use in the United States.

Tomosynthesis Acquisition & Reconstruction

Linear Tomography

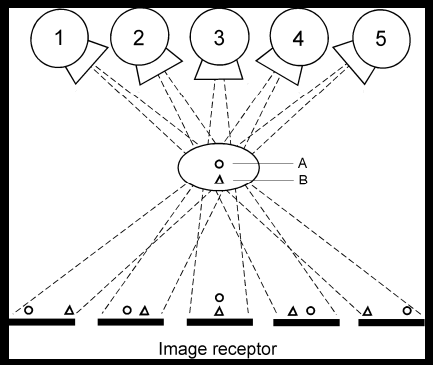

Simple Tomosynthesis

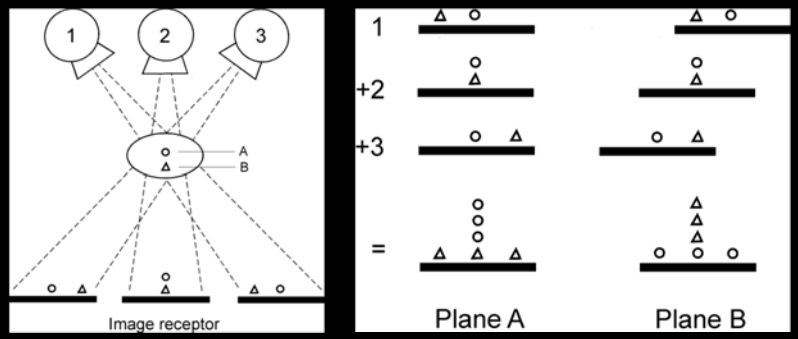

Acquisition geometry | Backprojection image formation

Geometry of Breast Tomosynthesis

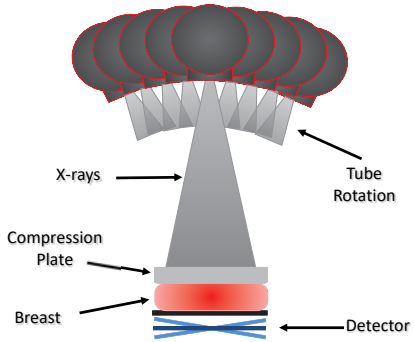

- DBT systems use a partial isocentric geometry with a fixed detector.
- The x-ray tube rotates around the breast in an arc.
- The detector either remains stationary or rotates with the tube.

Tomosynthesis Acquisition & Reconstruction

Fourier slice theorem

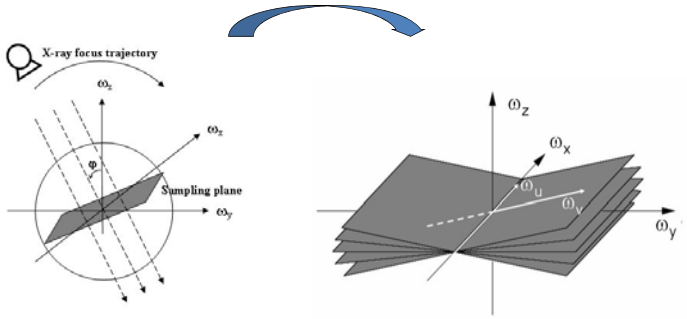

Geometry of Breast Tomosynthesis

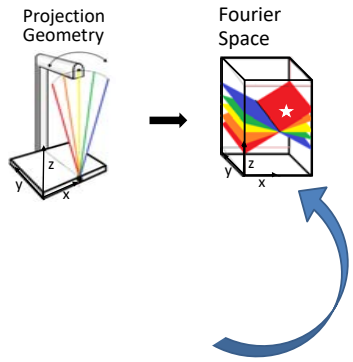

Each projection fills a single plane in the Fourier Domain.

Each projection selects objects oriented parallel to the projection.

Geometry of Breast Tomosynthesis

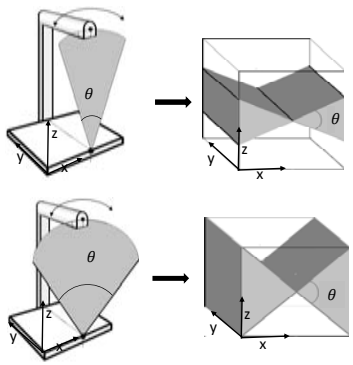

The angular range of the x-ray tube defines the non-zero region of the Fourier domain.

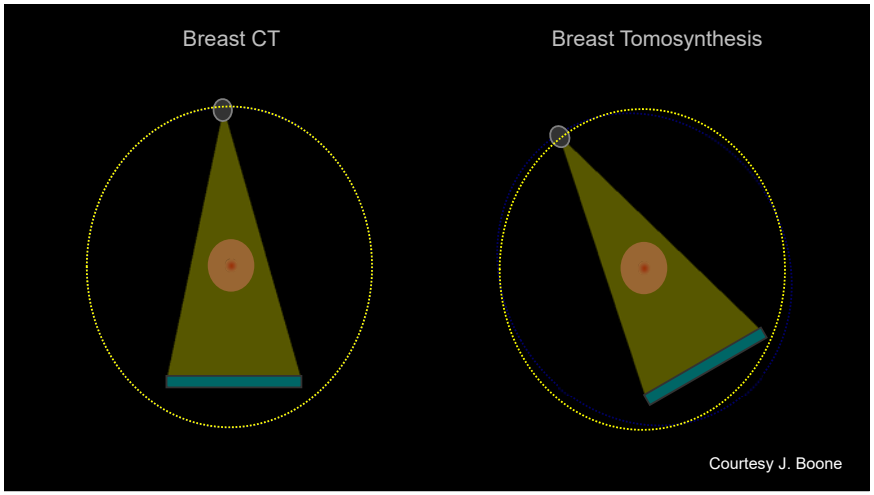

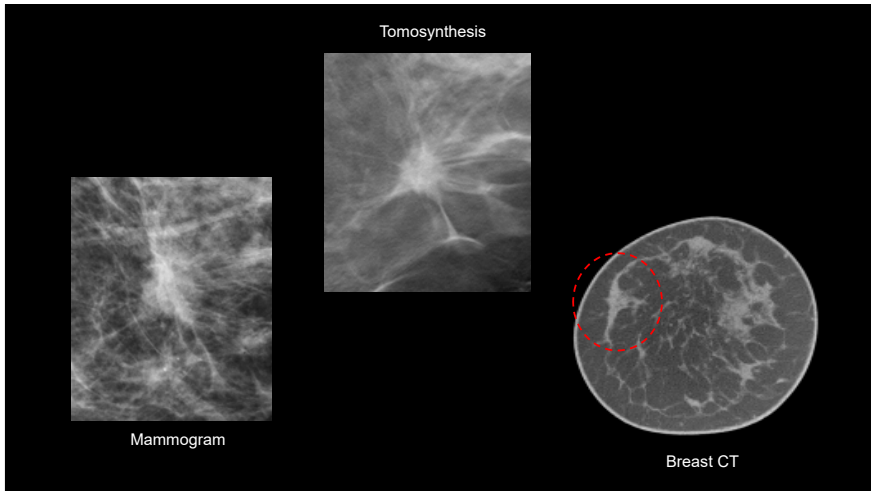

CT, Tomosynthesis, and Radiography

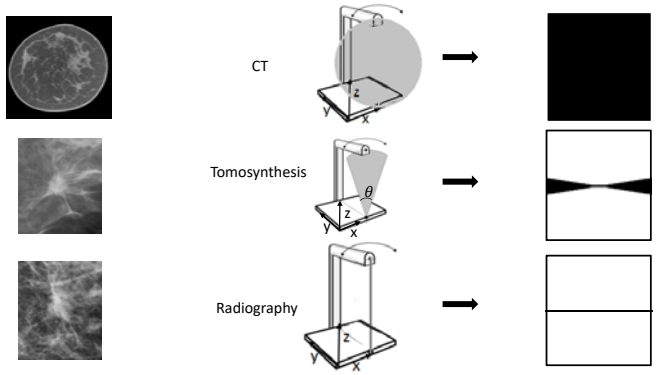

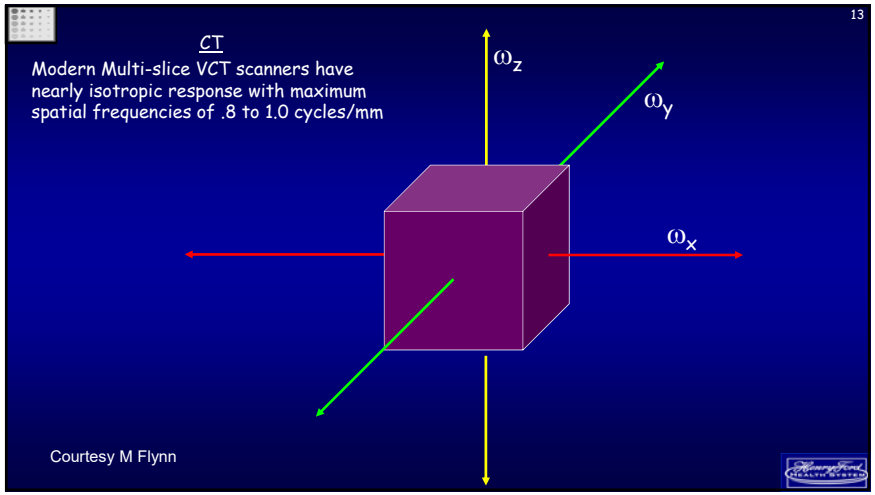
13
CT
Modern Multi-slice VCT scanners have nearly isotropic response with maximum spatial frequencies of .8 to 1.0 cycles/mm
ω_z
ω_y
ω_x
Courtesy M Flynn

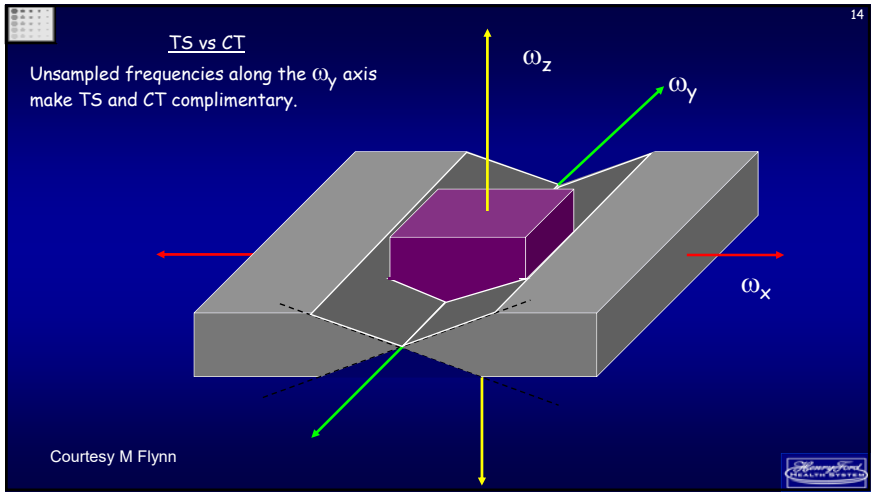
14
TS vs CT
Unsampled frequencies along the ω_y axis make TS and CT complimentary.
ω_z
ω_y
ω_x
Courtesy M Flynn

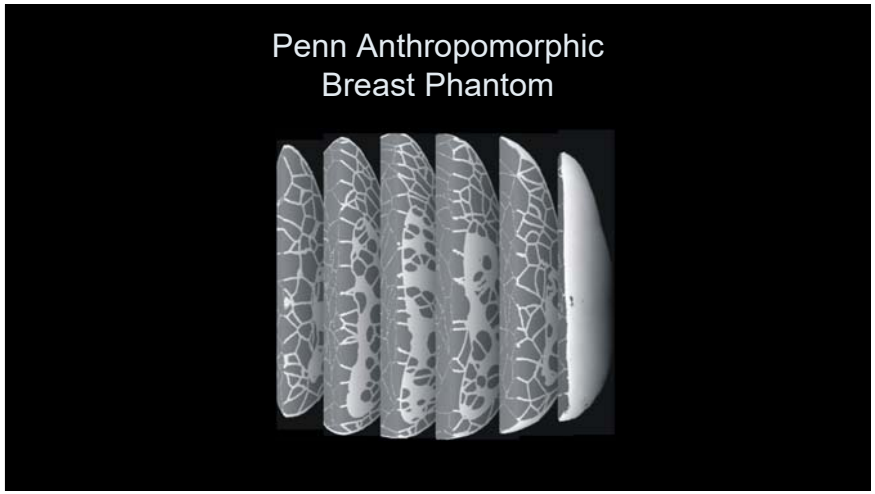
Penn Anthropomorphic Breast Phantom

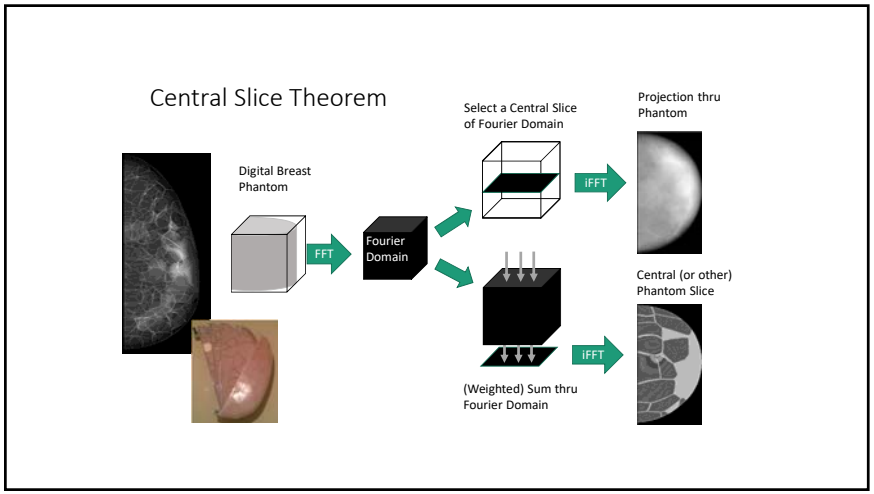
Central Slice Theorem
Digital Breast Phantom
FFT
Fourier Domain
Select a Central Slice of Fourier Domain
iFFT
Projection thru Phantom
(Weighted) Sum thru Fourier Domain
iFFT
Central (or other) Phantom Slice

CT, Tomosynthesis, and Radiography

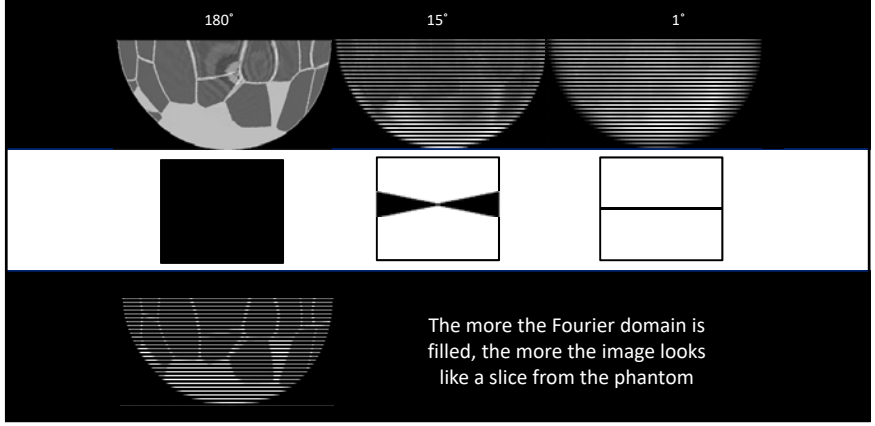

Angular range

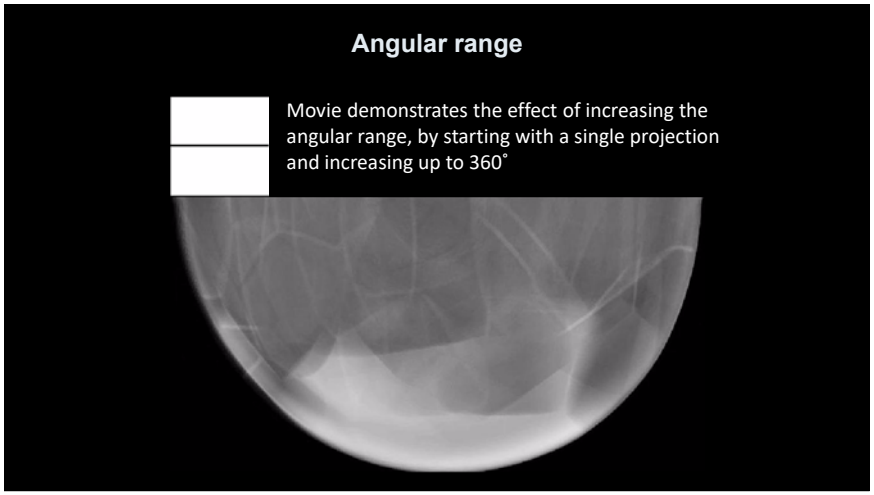

Angular range

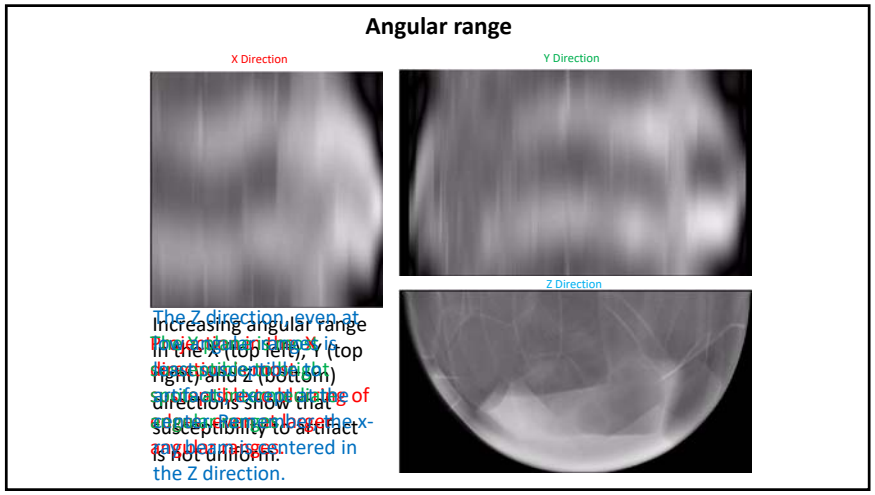

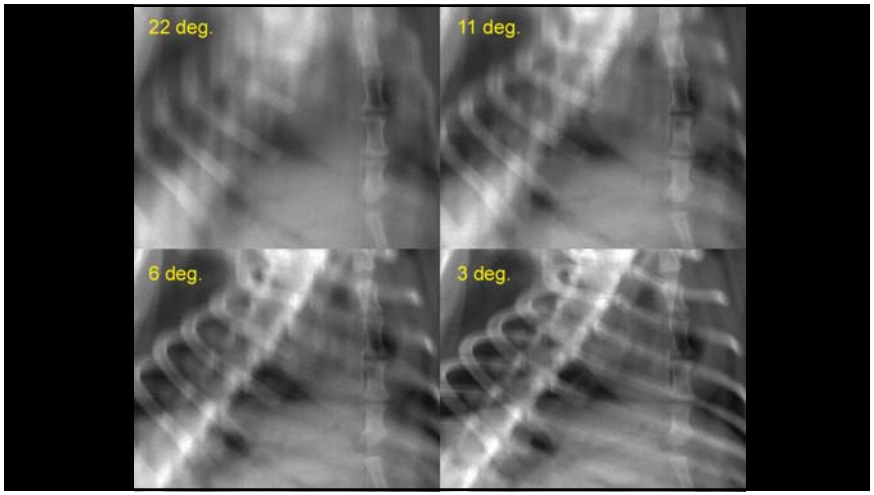

Angular range

Movie demonstrates the effect of increasing the angular range, starting with at 1˚ and increasing to 360˚, with the same number of projections.

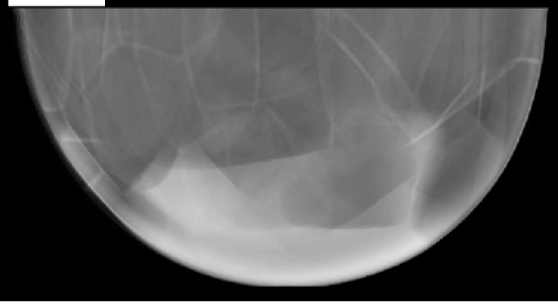

Angular range

Axial (XY) Plane – 15 Projections

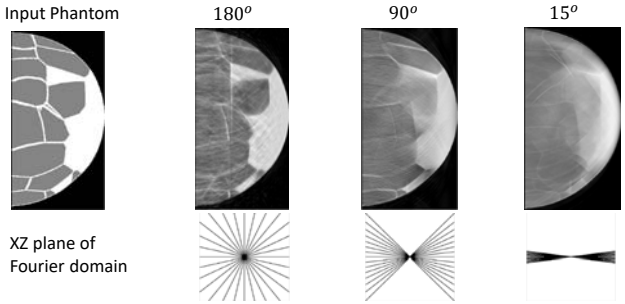

- At larger range, certain features are more in focus than others
- Undersampling artifacts are introduced

Number of projections

Movie demonstrates the effect of increasing the number of projections within a fixed angular range, starting with one projection.

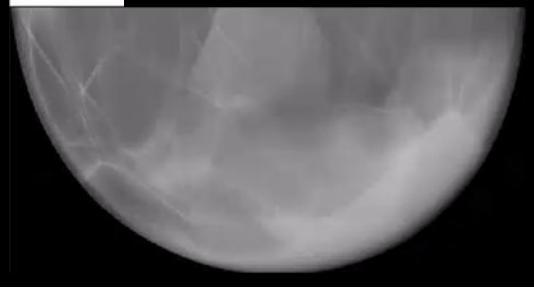

Number of projections

Axial Plane - 15° angular range

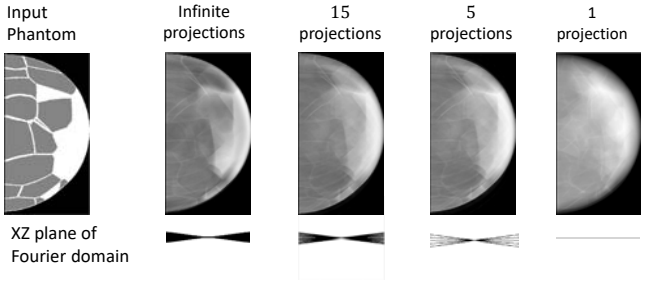

- Although the images become progressively sharper, the difference is most noticeable from 1 projection to 5 projections



Contrast and SDNR

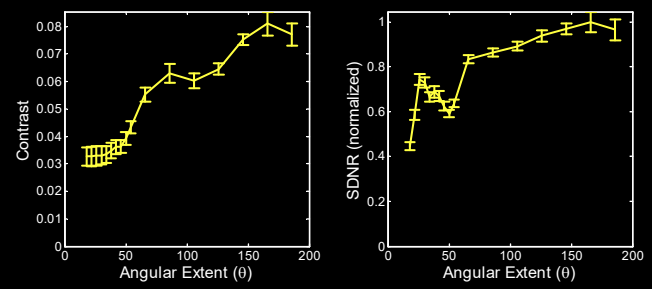

Angular Spacing, $\Delta\theta$=2°

Courtesy M.J. Yaffe

Commercial Systems

X-Ray Generation

X-Ray Tube
- Tungsten (W) Anode
- LFS: 0.3 mm; SFS: 0.1 mm

X-Ray Filtration
- Conv: 50 µm Rh; 50 µm Ag
- Tomo: 0.7 mm Al
- I-View: 0.3 mm Cu

X-Ray Generator
- Max mA varies with kVp
  - 20 – 39 kVp for 2D
  - 20 – 49 kVp for 3D
- LFS: 200 mA max; SFS: 50 mA max

HOLOGIC

HOLOGIC

Image Acquisition: 2D Conventional

- a-Se detector, 24×29 cm area
- 70 µm pixel size
- Rh and Ag filters
- Linear grid or HTC grid used in contact mode
- No grid in magnification mode

HOLOGIC

HOLOGIC

Image Acquisition: 15 Projection Tomosynthesis

Scan Details

- Al filter
- No anti-scatter grid
- Moving tube, 15° sweep
- Moving detector
- ~4 seconds acquisition
- Image resolution comes in two options:

Standard Resolution

- Projections: 140 µm pixel size
- Reconstruction
  - ~100 µm pixel size
  - 1 mm slice spacing

Clarity HD (Hi-Res Tomo)

- Projections: 70 µm pixel size
- Reconstruction
  - 70 µm pixel size
  - 1 mm slice spacing

HOLOGIC

HOLOGIC

Image Acquisition Modes

Conventional
- Acquires 2D image only

Tomo
- Acquires tomosynthesis images only

TomoHD
- Acquires tomosynthesis images only
- Produces synthetic 2D image (C-View or Intelligent 2D)

Combo
- Acquires tomosynthesis images
- Acquires 2D image

ComboHD
- Acquires tomosynthesis images
- Acquires 2D image
- Produces synthetic 2D images (C-View or Intelligent 2D)

HOLOGIC

HOLOGIC

Hologic Selenia Dimensions / 3Dimensions

- 2D and 3D under same compression
- Tube Anode: W
- Focal Spot: 0.1 mm / 0.3 mm
- Filtration: Rh/Ag (2D) / Al (3D)
- 15 degree continuous sweep
- 15 images, 3.7 s acquisition
- 70 cm SID
- Retractable grid
- 24 x 29 cm Selenium Direct detector
- 70 µm dels (140 µm, when binned)
- FBP Reconstruction
- 70 µm / 100 µm Reconstruction
- 1 mm slice spacing
- Synthetic 2D images

Fuji ASPIRE Cristalle

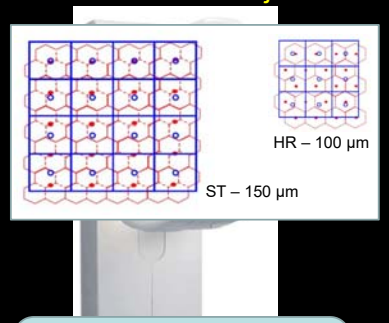

- Two acquisition modes (ST and HR)
- Hexagonal pixel detector gives higher resolution, but can cause artifacts
- 3 doses (L – low, N – normal, H – high)

- 2D and 3D under same compression
- Tube Anode: W
- Focal Spot: 0.1 mm / 0.3 mm
- Filtration: Rh (2D) / Al (3D)
- 15/40 degree continuous sweep
- 15 images, 4/9 s acquisition
- 65 cm SID
- Retractable grid
- 24 x 30 cm Selenium Direct detector
- 70/140 µm hex. dels (2D 50 µm eff.)
- FBP Reconstruction
- 100 / 150 µm Reconstruction
- 1 mm slice spacing
- Synthetic 2D images

Siemens Revelation / Inspiration

- Large sweep angle and 25 projections
- Wide (50°) sweep improves images of masses, but may degrade calcifications.
- Long exposure time can cause motion

- 2D and 3D under same compression
- Tube Anode: W
- Focal Spot: 0.15 mm / 0.3 mm
- Filtration: Mo/Rh (2D) / Rh (3D)
- 50 degree continuous sweep
- 25 images, 25 s acquisition
- 65 cm SID
- Grid or software scatter removal
- 24 x 30 cm Selenium Direct detector
- 85 µm dels
- FBP Reconstruction
- 80 µm Reconstruction
- 1 mm slice spacing
- Synthetic 2D images

GE Senoclaire/Pristina

- Only system with step & shoot acquisition
- Only system with CsI detector
- Smallest number of projections
- Iterative reconstruction method
- Slice / thin-slab / thick-slab recons

- 2D and 3D under same compression
- Tube Anode: Mo/Rh
- Focal Spot: 0.1 mm / 0.3 mm
- Filtration: Mo/Rh (2D) / Rh/Ag (3D)
- 25 degree step & shoot
- 9 images, 9 s acquisition
- 66 cm SID
- Moving grid
- 24 x 30 cm CsI Indirect detector
- 100 µm dels
- Iterative Reconstruction
- 100 µm Reconstruction
- 0.5 mm or 1 mm slice spacing
- Synthetic 2D images

Technical Specs

	Hologic	GE	Siemens	Fuji	IMS	Metaltronica	Planmed
Tube Motion	Continuous	Step & Shoot	Continuous	Continuous	Step & Shoot	Continuous	Sync & Shoot
# Projections	15	9	25	15	13	11/13/19	15
Sweep Angle	15	25	40	15/40	40 (var.)	15/24/36	30
Scan Time (s)	3.7	9 (*)	25	4/9	12	11/13/19	7
Grid	No	Yes	No	No	No	Yes	No
Recon Algo.	FBP	Iterative	FBP+	FBP	Iterative	FBP	Iterative
Del Size (um)	70/140	100	85	70 (50)	85	85	80
Voxel Size (um)	70/100	100	80	100/150	85	85	95/140

Contrast Sensitivity

Mammo-like (Hologic/GE/Fuji) CT-like (Siemens)

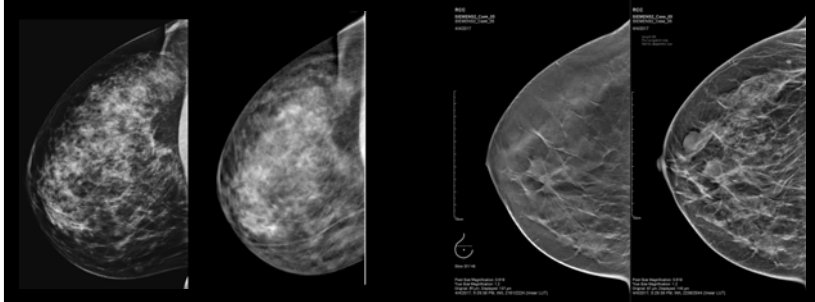

2D 3D Conventional New - Empire

In-plane Spatial Resolution (MTF)

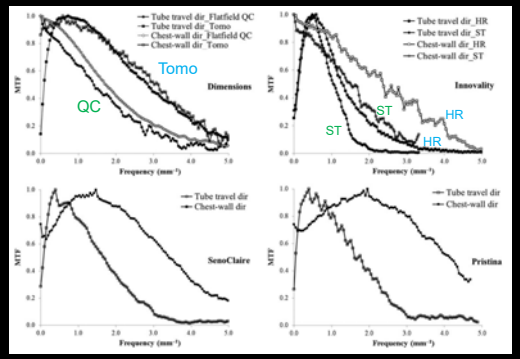

Observations:

- The resolution is assymetric in X and Y
- Reconstruction algorithm affects resolution
- Voxel size affects resolution

NB: These MTF graphs show the relative response in X & Y. They have been normalized to a maximum of 1. The OTF in X and Y has a common value at zero frequency.

Ortenzia, *et al*. Physical characterisation of four different commercial digital breast tomosynthesis systems 2018 RPD DOI: 10.1093/rpd/ncy024

Slice-Sensitivity Profile (SSP) and Artifact Spread Function (ASF)

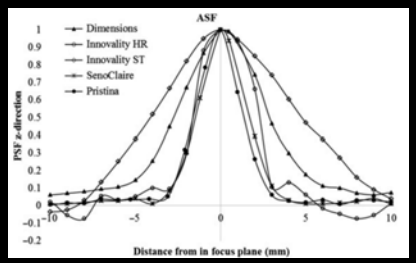

SSP for four systems. Results show the impact acquisition geometry and reconstruction method.

DBT system	Scan angle	FWHM beads left of centre (mm)	FWHM beads right of centre (mm)
Dimensions	15°	3.50	3.50
Innovality ST	15°	5.00	5.25
Innovality HR	40°	2.00	2.25
SenoClaire	25°	2.25	2.25
Pristina	25°	3.00	2.25

Ortenzia, *et al*. Physical characterisation of four different commercial digital breast tomosynthesis systems 2018 RPD DOI: 10.1093/rpd/ncy024

Slice Sensitivity Profile



Maki, *et al*, Medical Physics, 2016

Slice Sensitivity Profile

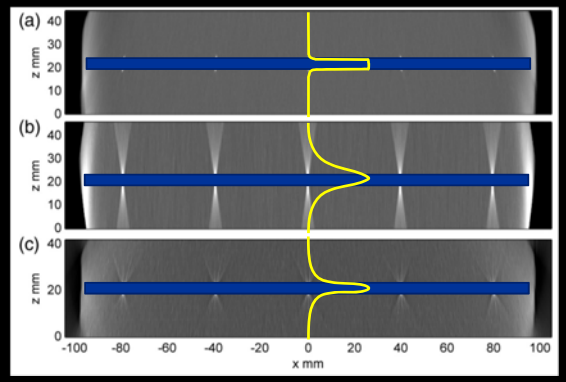

Maki, *et al*, Medical Physics, 2016

Slice Sensitivity Profile

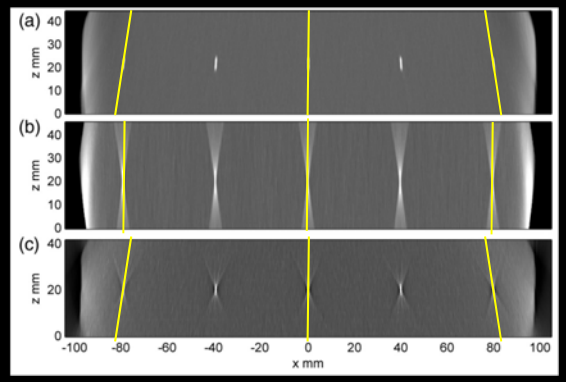

Maki, *et al*, Medical Physics, 2016

Clinical Performance

Masses vs. Calcs

Pooled ROC curves for 2 reader studies

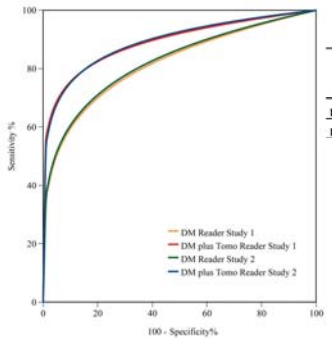

Area under the ROC curve

	DM	DM † plus Tomo	Difference	p-value	95% CI
Reader Study 1	82.1	89.4	7.2	<0.001	3.7 , 10.8
Reader Study 2	82.8	89.5	6.8	<0.001	4.1 , 9.5

Using probability of malignancy scores; curves represent average ROC performance for 12 readers in study 1 and 15 in study 2.

Rafferty E A et al. Radiology doi:10.1148/radiol.12120674

Radiology

Pooled ROC by Lesion Type

Calcifications

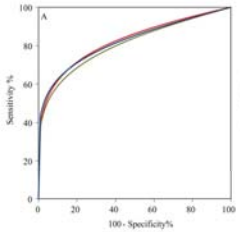

Non-calcified

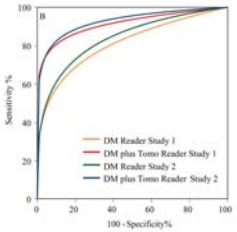

Area under the ROC curve

Case Type	Reader Study	DM †	DM plus† Tomo	Difference	p-value	95% CI
Calcification	1	80.4	84.0	3.5	0.073	-0.4 , 7.4
	2	81.7	83.1	1.4	0.082	-0.2 , 2.9
Non -Calcification	1	80.7	91.2	10.4	<0.001	4.7 , 16.1
	2	84.2	93.0	8.8	<0.001	5.1 , 12.5

Rafferty E A et al. Radiology doi:10.1148/radiol.12120674

Radiology

Digital mammography image of an invasive ductal carcinoma.

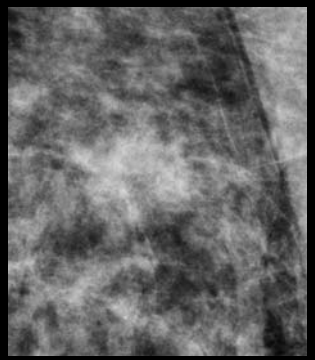

Rafferty E A et al. Radiology doi:10.1148/radiol.12120674

Radiology

Tomosynthesis image of an invasive ductal carcinoma.

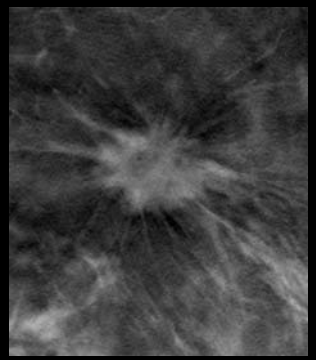

Rafferty E A et al. Radiology doi:10.1148/radiol.12120674

Radiology

Visualization of micro-calcifications

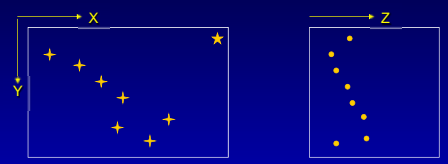

Simulated pattern of clustered μCas (Pattern: Big Dipper and Pole Star)

Distribution along z-direction

Conventional mammography:
- Clustered μCa are projected onto a 2-D plane.
- The pattern of μCa distribution is obvious.
- The pattern of μCa distribution contains important diagnostic information.

Visualization of micro-calcifications

DBT reconstruction

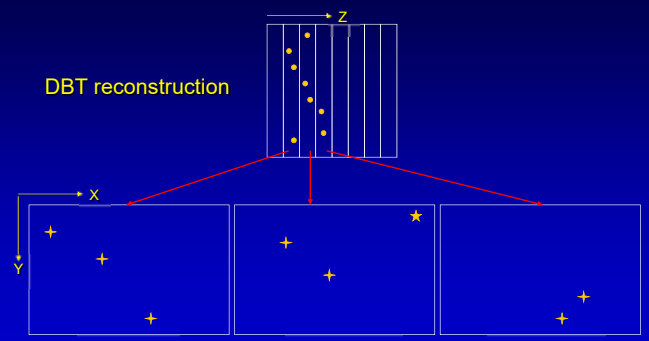

DBT slice N | DBT slice N+1 | DBT slice N+2

The pattern of μCa cluster is lost.

Thin MIPS

Visualization of micro-calcifications

"Slab View" for showing clustered μCa:
- Combine multiple slices into a "slab"
- Maximum intensity projection (MIP) within the slab
- Slide the "slab window" through the reconstruction

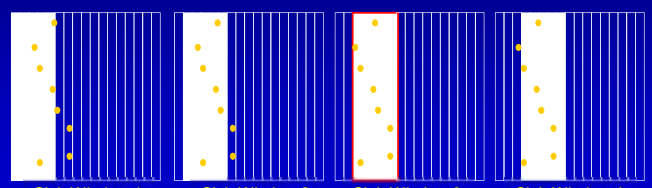

Slab Window 1 | Slab Window 2 | Slab Window 3 | Slab Window 4

Visualization of micro-calcifications

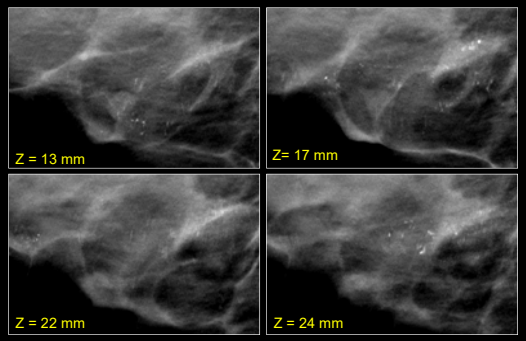

DBT reconstruction (1 mm slice)

Visualization of micro-calcifications

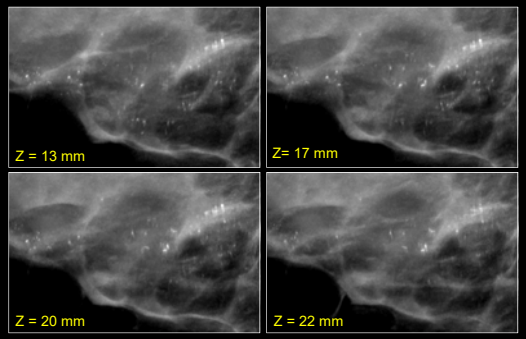

Slab View: 10 mm slab

Synthetic 2D Images

(Thick MIPS)

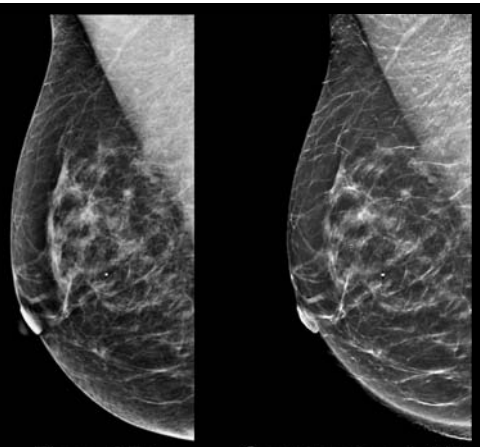

True 2D Synthesized 2D

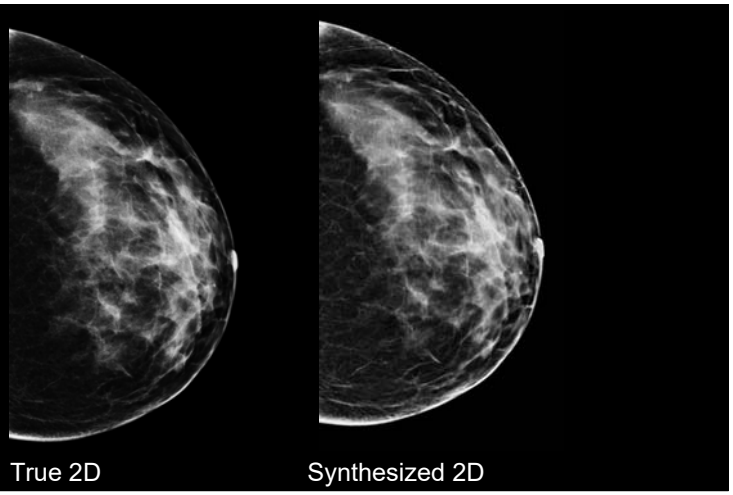

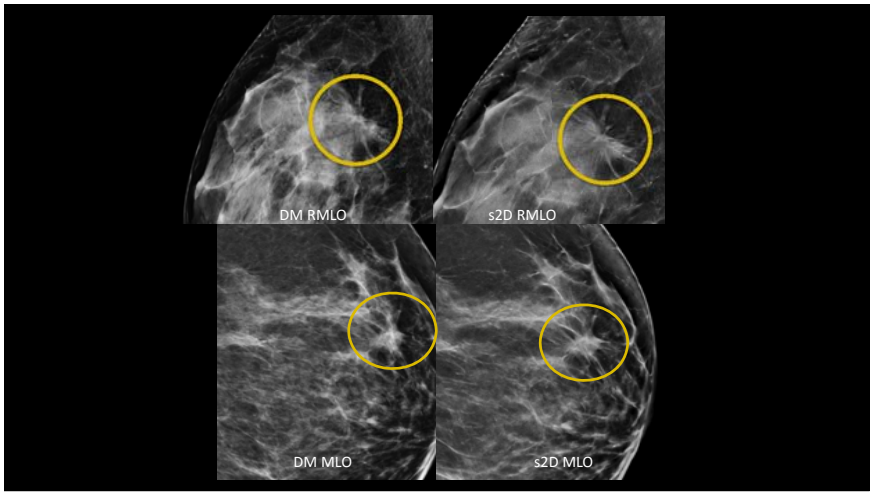

Good – Calcs can be seen better in some cases

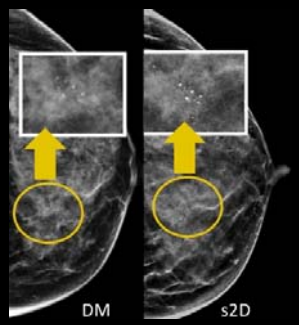

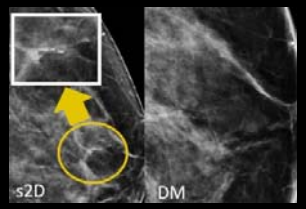

Bad – False calcs can be seen. These arise from the thick slices of DBT.

2D vs 3Ds

Hologic FDA data:

- 302 subjects
- 15 readers
- 3Ds superior to 2D alone
- ΔAUC = 0,04 (p=0.005)
- Recall Rate reduced by 30.2%

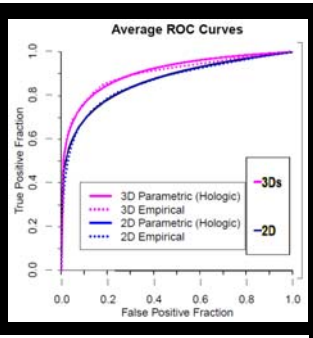

Mode	FFDM Views	DBT Views	Synthesized Views	Exam Dose per Breast
FFDM	MLO + CC	-	-	2.4 mGy
FFDM + 3D MLO	MLO + CC	MLO	-	3.85 mGy
FFDM + DBT	MLO + CC	MLO + CC	-	5.3 mGy
DBT + Synthesized 2D	-	MLO + CC	MLO + CC	2.9 mGy

Dose

Determinants of Dose

X-ray Beam Quality
- kVp
- Filtration
- Total mAs

Angular Exposure
- Change in SID
- Collimation
- Dose Depth Dependence

Projection Factors
- Number of projections
- mAs per projection
- Technical Limitations (det./gen.)

Dose Determines Lesion Detectability

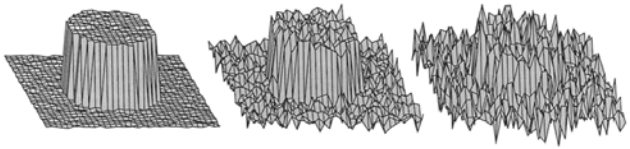

High Dose | Medium Dose | Low Dose

For an ideal detector, the dose for tomosynthesis should be equal to or less than the dose for digital mammography

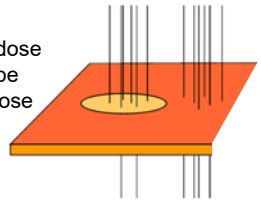

DBT Dose (Phantom)

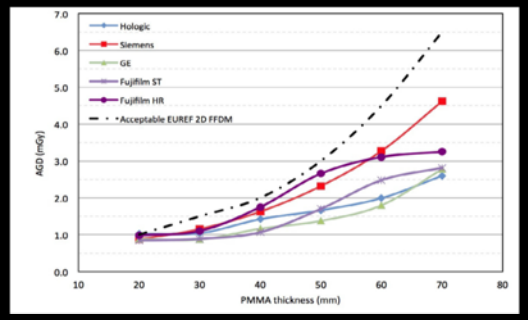

Maldera *et al*, Physica Medica, 33 (2017)

DBT Dose vs. DM Dose

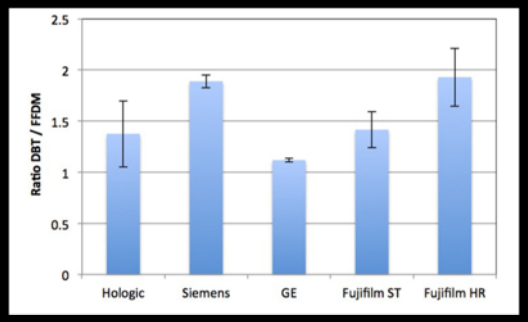

Maldera *et al*, Physica Medica, 33 (2017)

Average dose per image

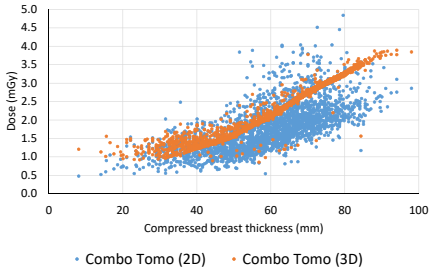

This can be attributed to the difference in phototimer operation in 2D and 3D. As shown here, the 3D dose is primarily determined by breast thickness. The dose is only increased for very dense breasted women. In 2D, the dose is determined by breast thickness *and* glandularity.

Average dose per patient*

Mode	No. Patients	View Position	No. Images Acquired	Average Dose per Patient (mGy)	Average Compressed Breast Thickness (mm)
Tomo Combo (2D)	2,454	CC	5,125	1.84	58.50
		MLO	5,799	2.52	64.54
Tomo Combo (3D)	2,454	CC	4,901	2.16	58.50
		MLO	4,893	2.49	64.54

Mode (Combined MLO and CC)	Average Dose per Patient (mGy and % of total)	Average Compressed Breast Thickness (mm)
Tomo Combo (2D)	4.36 (48.4%)	61.52
Tomo Combo (3D)	4.65 (51.6%)	60.54

The 2D component of the Tomo Combo acquisition accounted for nearly half of the average dose per patient in 2014.

*Information provided by the DICOM header that corresponds to the mean glandular dose in mGy (Organ Dose 0040,0316)

Average dose per patient

Mode	No. Patients	View Position	No. Images Acquired	Average Dose per Patient (mGy)	Average Compressed Breast Thickness (mm)
Tomo Combo (2D + 3D)	2,454	CC	10,026	4.00	58.50
		MLO	10,692	5.01	64.54
Tomo HD (C-View + 3D)	2,064	CC	4,290	2.29	57.60
		MLO	4,427	2.77	63.47

Mode (Combined MLO and CC)	Average Dose per Patient (mGy)	Average Compressed Breast Thickness (mm)
Tomo Combo (2D + 3D)	9.01	61.52
Tomo HD (C-View™ + 3D)	5.06	60.54

- 44% *

The switch to Tomo HD in 2015 eliminated the acquisition of 2D images. This resulted in an overall dose reduction of 44% in our patient population.

* p-value is infinitesimal

Average dose per patient

Mode	No. Patients	View Position	No. Images Acquired	Average Dose per Patient (mGy)	Average Compressed Breast Thickness (mm)
Tomo Combo (3D)	2,454	CC	4,901	2.16	58.50
		MLO	4,893	2.49	64.54
Tomo HD (3D)	2,064	CC	4,290	2.29	57.60
		MLO	4,427	2.77	63.47

Mode (Combined MLO and CC)	Average Dose per Patient (mGy)		Average Compressed Breast Thickness (mm)
Tomo Combo (3D only)	4.65		61.52
Tomo HD (3D only)	5.06	+9% *	60.54

In changing from Tomo Combo to Tomo HD, the 3D component of the patient dose is increased by 9%, due to additional images.

* p < 1e-38

Patient dose by breast thickness

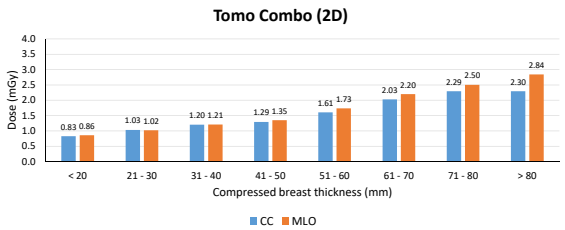

The amount of breast compression and radiation dose that is applied during the mammography exam influences image quality.

Thick breasts are exposed to substantially increased radiation dose.

Patient dose by breast thickness

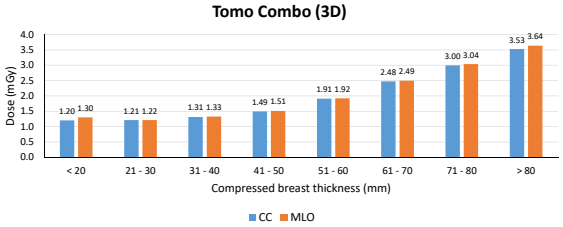

The increase of dose with breast thickness is more significant with 3D images than 2D images.

The relative increase in dose is thickness and projection dependent.

Patient dose by breast thickness

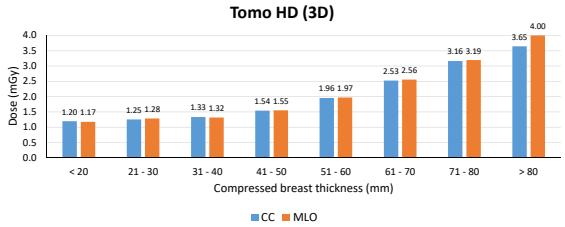

There is only a slight difference in the dose of the 3D images in the Tomo HD and Tomo Combo modes, when stratified by thickness.

The greatest increase in dose is associated with thick (i.e., large) breasts.

Patient dose by age

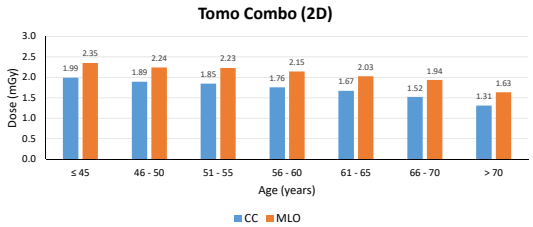

Generally, it is expected that older women have less glandular breast tissue, i.e., lower breast density. Thus, patient dose decreases with age.

This is true with the Tomo Combo 2D image dose. This trend is not seen to the same degree with Tomo Combo 3D or Tomo HD 3D images (next slide).

Patient dose by age

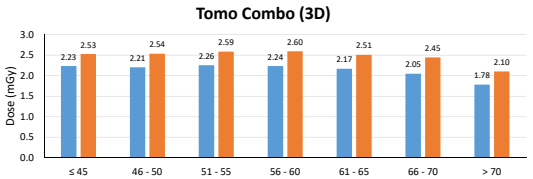

Generally, it is expected that older women have less glandular breast tissue, i.e., lower breast density. Thus, patient dose decreases with age.

This is true with the Tomo Combo 2D image dose. This trend is not seen to the same degree with Tomo Combo 3D or Tomo HD 3D images (next slide).

Patient dose by age

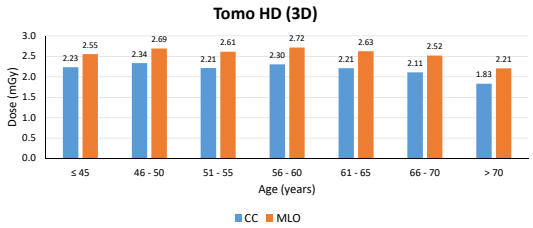

Generally, it is expected that older women have less glandular breast tissue, i.e., lower breast density. Thus, patient dose decreases with age.

This is true with the Tomo Combo 2D image dose. This trend is not seen to the same degree with Tomo Combo 3D or Tomo HD 3D images (next slide).

Artifacts

Moire Patterns, Aliasing, and Spectral Leakage

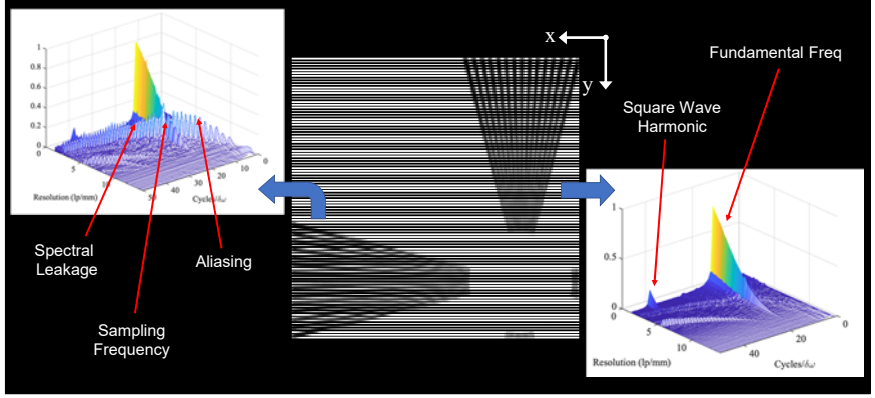

Impact of object **orientation**.



Impact of object **orientation**.

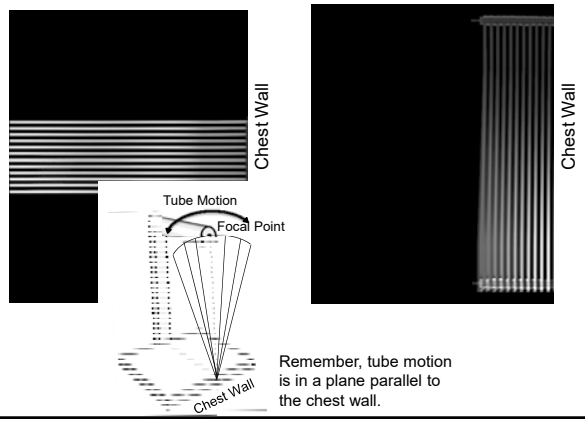

Remember, tube motion is in a plane parallel to the chest wall.

Object location



- This video demonstrates the effect of location on contrast and spatial resolution.
- The effect is varies with object height
- The image is always best at the chest wall.
- The difference is most noticeable at the bottom, where the phantom is thicker.

Object orientation

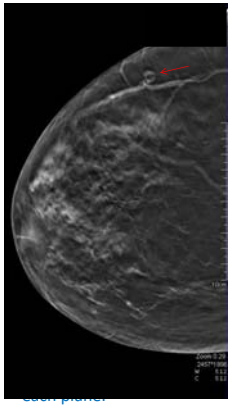

A looping vessel is not equally visualized at all angles.

The image to the right shows vessels in both parallel and perpendicular orientations, with the vessel parallel to the chest wall less well visualized.

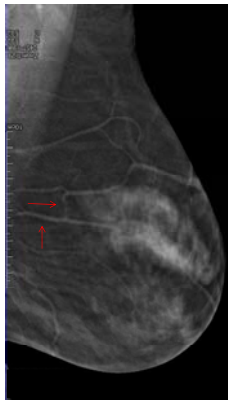

Object location and size



The location and size of an object can affect the image.

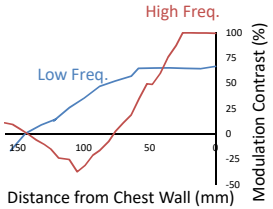

Object Size



- Note the diagonal region of blurring across the phantom.
- This represents the height at which the border of 2 adjacent objects cannot be resolved.

Object Size



- Below this line, the order of the air gap and the plastic is switched
- This is called aliasing. DBT is sensitive to aliasing.

Divergent Beam Anisotropy

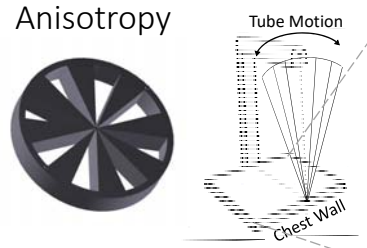

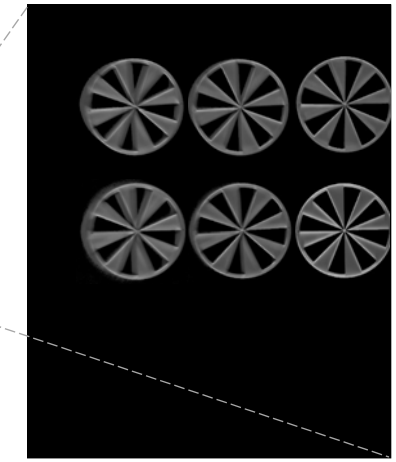

- "Thick" Radial phantom examines various frequencies and orientations in a small region
- The mid chestwall is in better focus than other locations, in agreement with the Defrise phantom

Attenuating Materials

- "Zipper" artifact due to repetition of out of plane structures
- Analogous to CT view aliasing caused by view undersampling

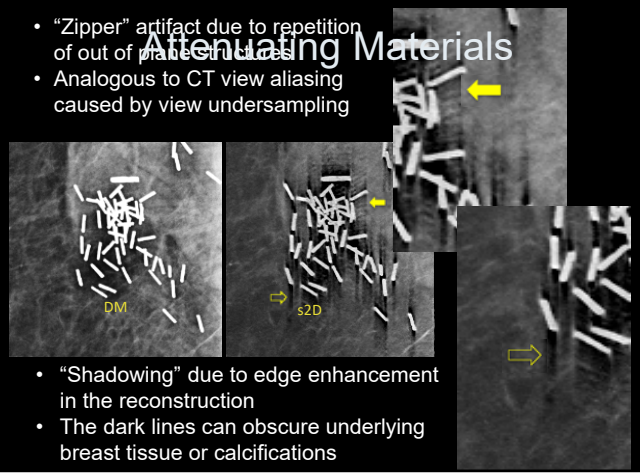

- "Shadowing" due to edge enhancement in the reconstruction
- The dark lines can obscure underlying breast tissue or calcifications

Attenuating Materials



Iterative reconstructions can reduce these artifacts. The zipper artifact is largely eliminated, while shadowing is diminished but still evident.

Motion Artifacts

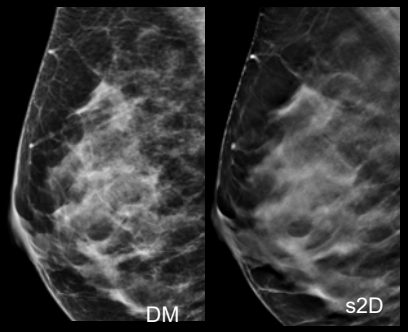

DBT and s2D images are more greatly affected by patient motion than DM because of the long acquisition time

Future Directions

1) Super-Resolution

Acquiring multiple low resolution images at sub-pixel spacing generates a high resolution (i.e., super-resolution) image.

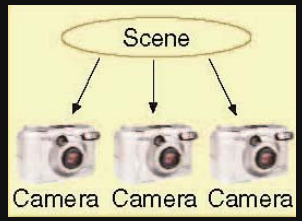

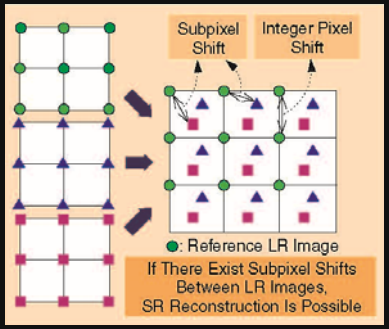



The reconstruction can distinguish frequencies higher than the detector alias frequency $0.5a^{-1}$ (3.6 lp/mm). This is not possible with a single projection.

Clinical Super-resolution

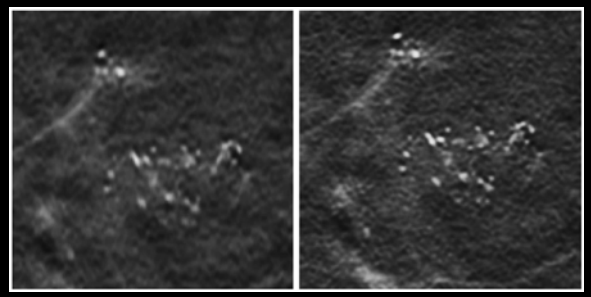

4x Mag 4x Super-resolution

Shimadzu – HD Tomosynthesis

2) Oblique Reconstructions

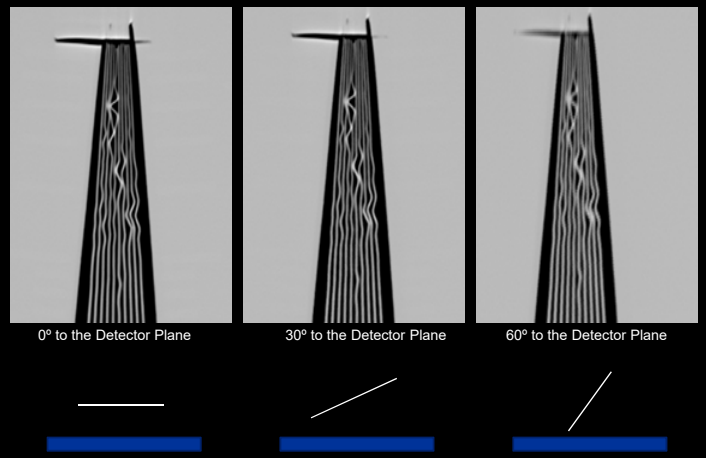

Clinical MPR

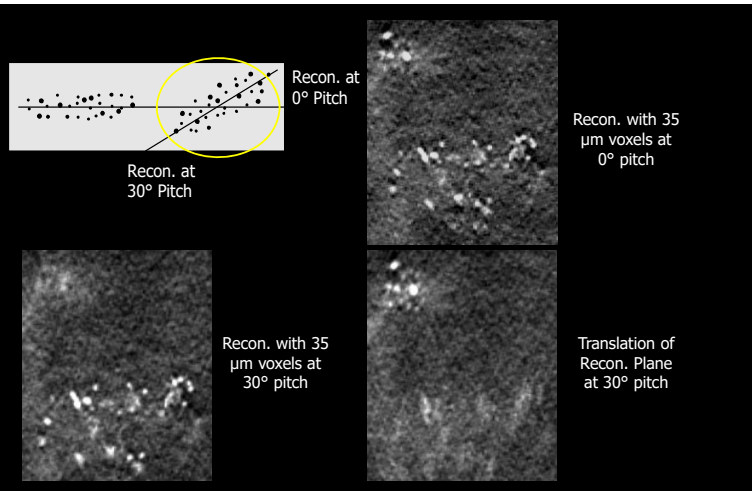

Shimadzu – Oblique Tomosynthesis

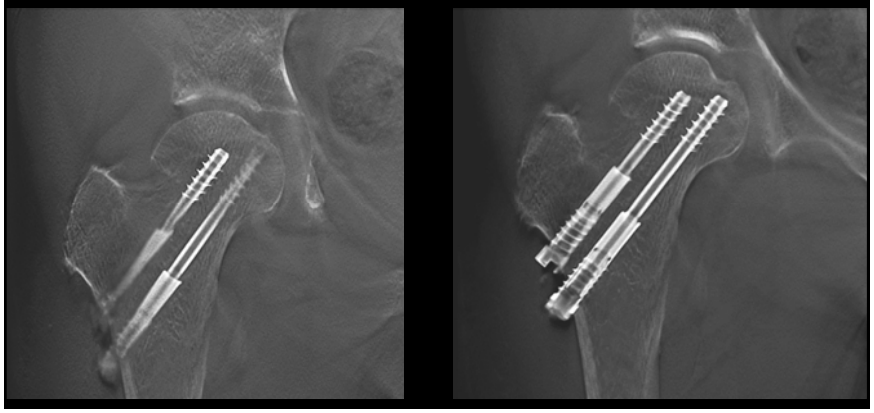

3) Volume Visualization

- Synthetic mammograms are created from perspective of the central projection
- Volume Visualization (V V) is a dynamic method of visualizing the breast from a set of oblique angles
- V V images provide the radiologist with a rotating 3D volume providing better perception of the tissue overlap

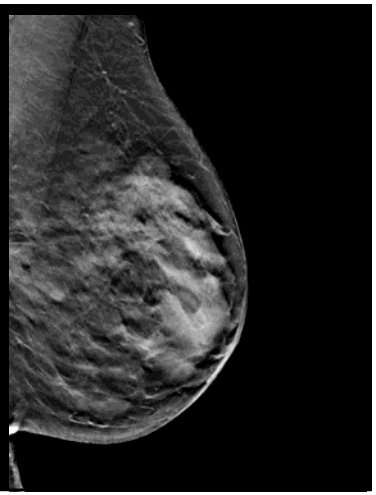

Next-Generation DBT

Next-Generation DBT



Isotropic in-plane limiting resolution - 10.5 lp/mm

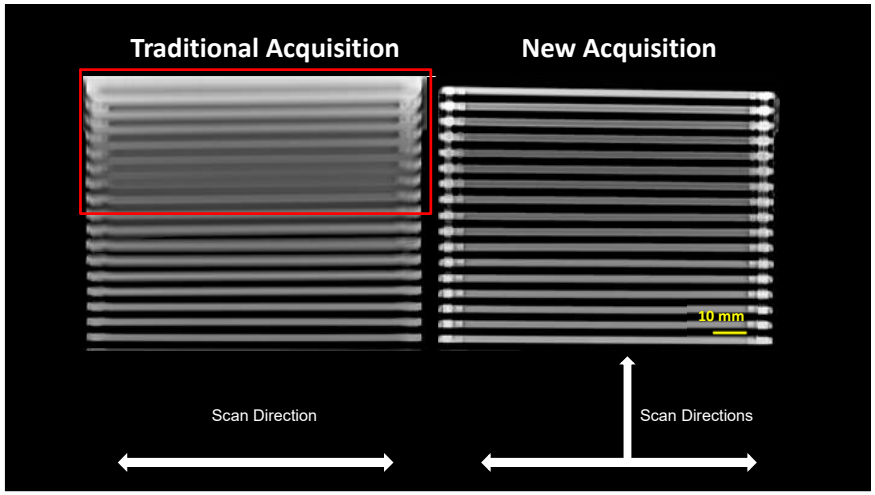
Traditional Acquisition
New Acquisition
10 mm
Scan Direction
Scan Directions

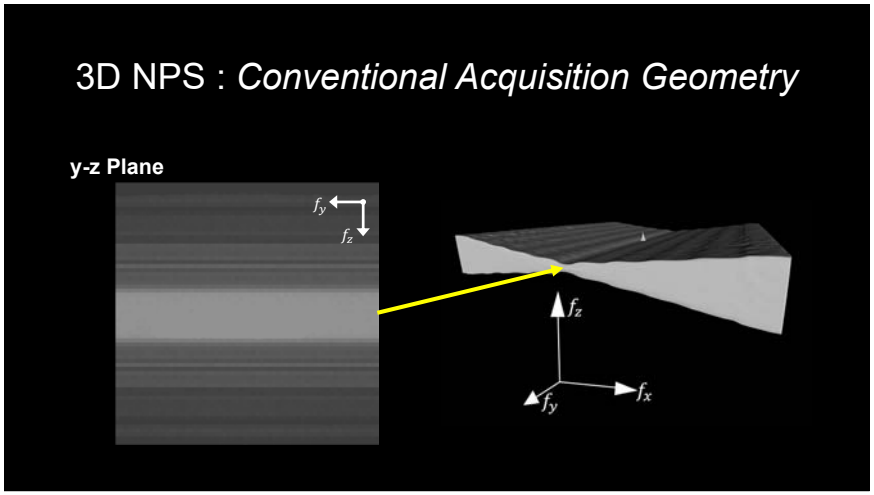
3D NPS : Conventional Acquisition Geometry
y-z Plane
f_y
f_z
f_x

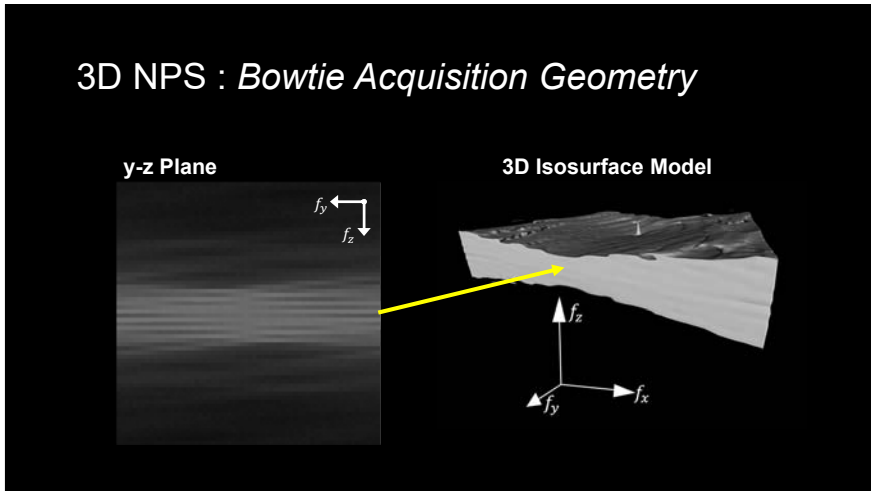
3D NPS : Bowtie Acquisition Geometry
y-z Plane
3D Isosurface Model
f_y
f_z
f_x

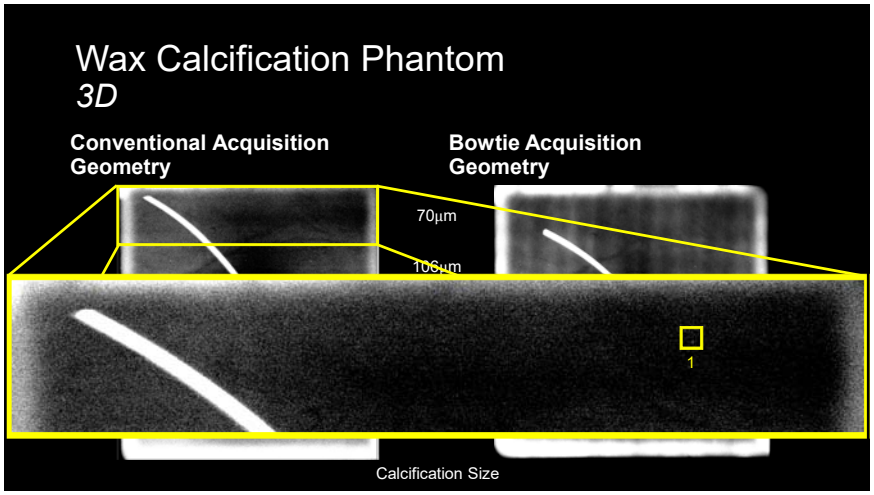
Wax Calcification Phantom
3D
Conventional Acquisition Geometry
Bowtie Acquisition Geometry
70µm
106µm
1
Calcification Size

Wax Calcification Phantom
3D



Anthropomorphic Phantom

Geometry I:
Conventional

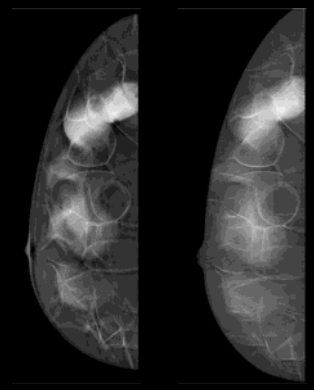

Geometry III:
PA Tube Motion

Advantages:

- Avoids depth dependent magnification
- Same pixel size for every slice
- Avoids blurred zone in slices near the detector
- Breast, correctly, is largest at the midplane
- Structures oriented laterally (L-R) are better removed

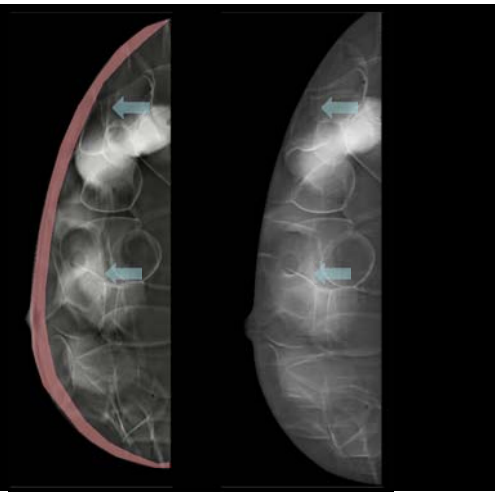

Magnification Digital Breast Tomosynthesis

Contact | Magnification 1.3 | Magnification 1.6

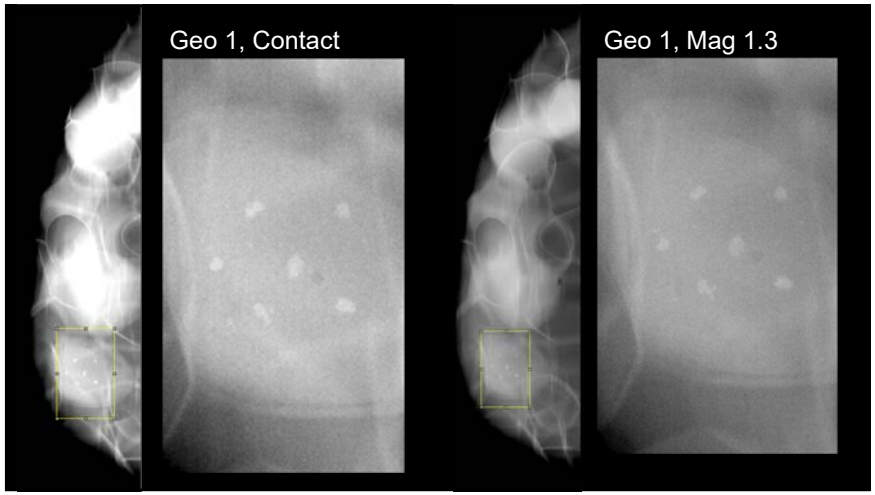



Hologic Prototype CE-DBT System

Target	W
kVp	49 (HE) / 32 (LE)
Filter	Cu (HE) / Al (LE)
SID	70 cm
Detector	3 fps, 2x2 binning
Angular Range	15°
Scan Time	7.3 seconds

- Separate calibrations for LE and HE images
- Manual technique, no AEC
- DE subtraction factor k derived from CIRS Model 20 BR3D phantom

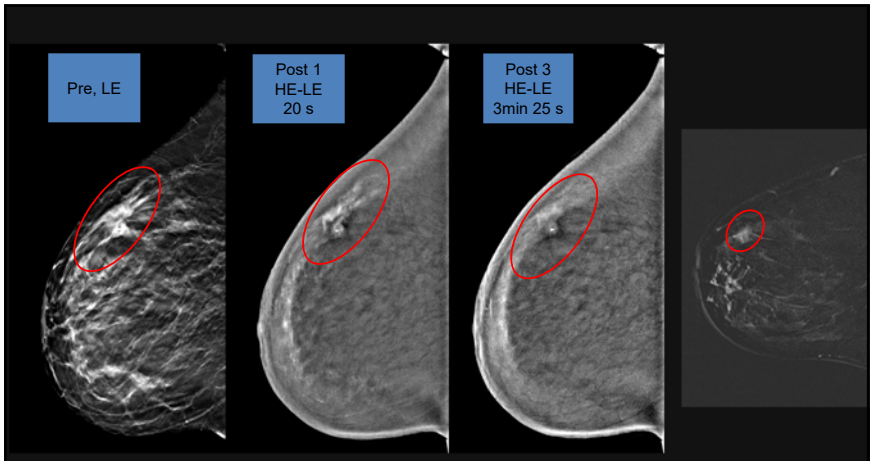

Carton AK, et al. British Journal of Radiology 83(988): 344-350, Apr 2010.

Advantages of tomosynthesis

- Improves conspicuity by removing overlying structures
- Sectional imaging with high resolution
- Can be performed in high volume screening
- Similar radiation dose to mammography
- Similar cost to mammography
- Good platform for quantitative imaging