

When the Physicist Becomes the Patient

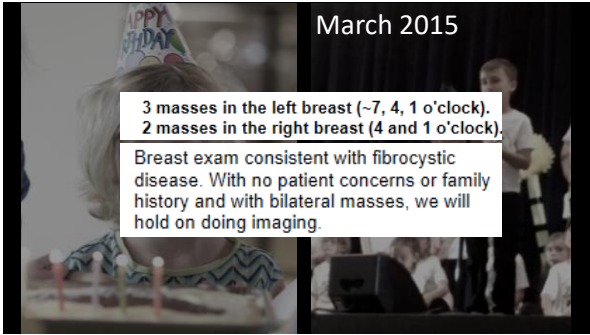
Rebecca Milman Marsh, Ph.D.
University of Colorado School of Medicine



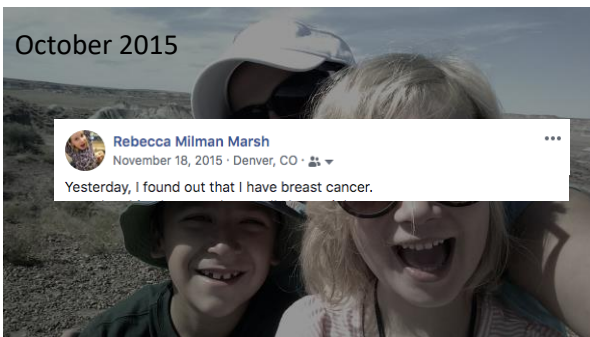
Disclosures:

- Nothing financial
- Participant in the *Share Triumph* project
- PG-13 language









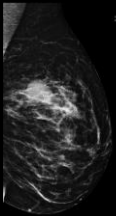
*"We all have our shit to deal with. Right now, this is mine."
-Me*

"Smart" people get cancer, too...

March 2015 → November 2015

3 masses in the left breast (~7, 4, 1 o'clock).
2 masses in the right breast (4 and 1 o'clock).

Breast exam consistent with fibrocystic disease. With no patient concerns or family history and with bilateral masses, we will hold on doing imaging.



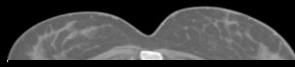
We all want answers.



We need to change how we think about dose from imaging procedures.



We need to change how we think about dose in imaging.

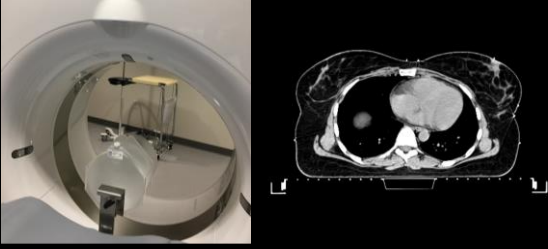


Stage 3 TNBC
[T2, N3b, M0]

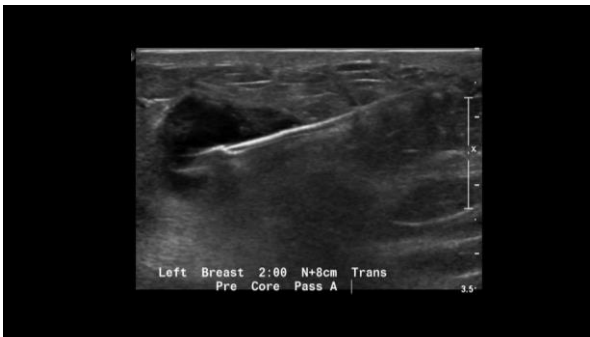5-year survival:
~50%

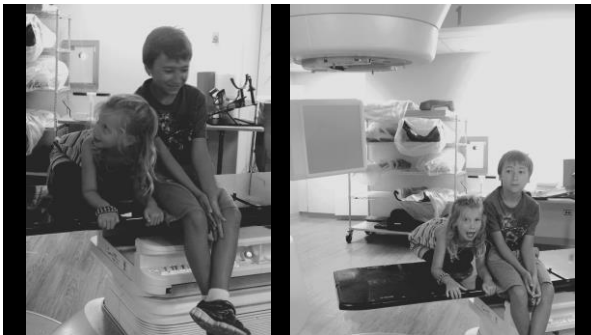Total mAs 4147		Total DLP 726 mGy*cm			
Scan	kV	mAs / ref.	CTDIvol mGy	DLP mGy*cm	
Patient Position F-SP					
Topogram	1	120	0.15(L)	11.21	
Topogram	2	120	0.15(L)	11.21	
CAP 70SEC	3	120 / 180	9.90(L)	703.73	

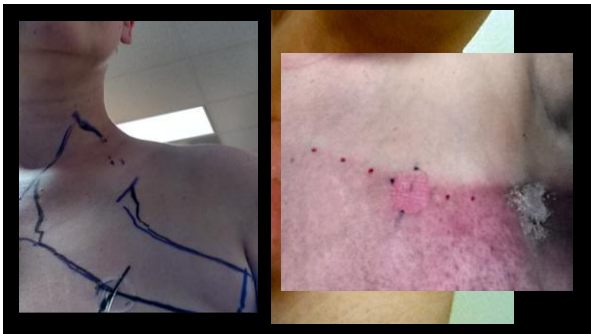Patients want to know what to expect.











**Many patients question everything
(and with good reason)**

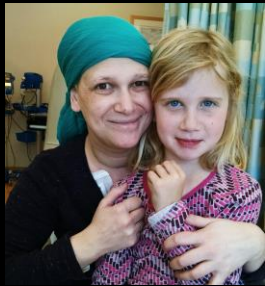NM RADIONUCLIDE THERAPY BY IV (Order 306533830)	
Reason for Exam	
Dx: Lymphedema of right upper extremity [I89.0 (ICD-10-CM)]	
Scheduling Instructions	
Pain from Bone Metastases	
DEXA SCAN (Order 306533833)	
Reason for Exam	
Evaluate bone density - on antiendocrine therapy	



Many patients question everything (and with good reason)

The "at least" dilemma...

- "At least you caught it early..."
- "At least you're young..."
- "At least it's not stage IV..."
- "At least your hair is growing back..."



Effects of treatment are long-lasting

- Physical
- Psychological
 - Financial
 - Health concerns







