4D DSA AND 4D FLUOROSCOPY:

Accelerated Applications using Undersampled Acquisition and Constrained Reconstruction

Chuck Mistretta

The University of Wisconsin, Madison

UW International Center for Accelerated Medical Imaging

Background: Time Resolved MR Angiography

During the past 12 years we have been investigating ways to accelerate MRA acquisition to achieve simultaneous high temporal and spatial resolution.

The key elements have included

1. The use of highly undersampled non-Cartesian k-space trajectories such as VIPR
2. The use of Constrained Reconstruction such as HYPR

These elements are compatible with parallel imaging and compressed sensing algorithms which can be used to provide additional acceleration.

Related principles led to the development of 4D DSA

3D Radial Undersampling VIPR

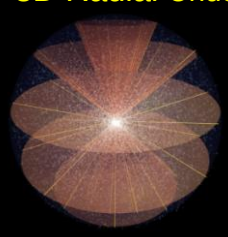

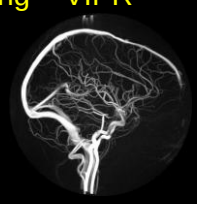

K. Johnson et al

36 x undersampling

AV. Barger Magn Reson Med., 48, 297-305,2002.



Artifact Removal SNR Restoration-- HYPR

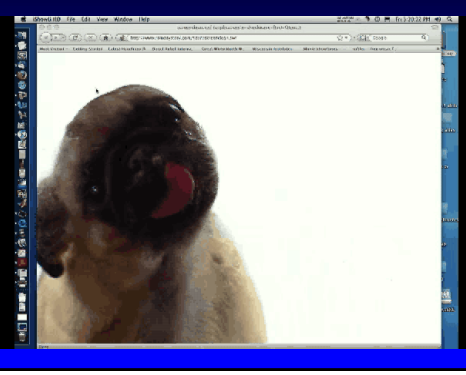



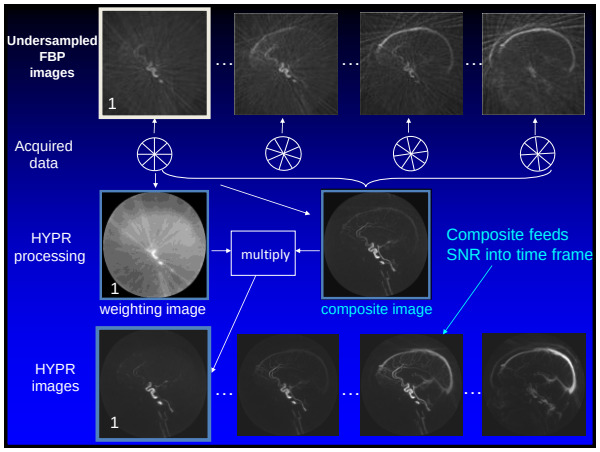

Comparison of Conventional and HYPR at 50X undersamplinng

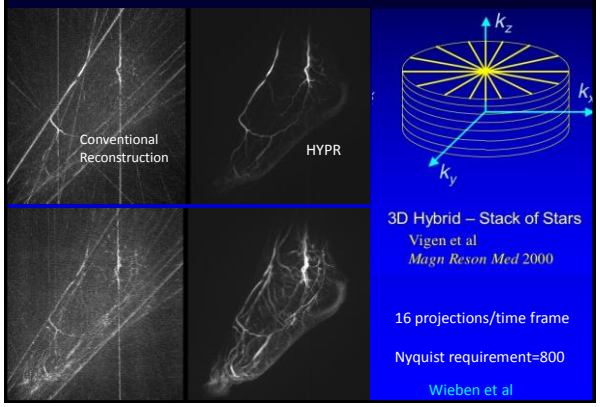

3D Hybrid – Stack of Stars
Vigen et al
Magn Reson Med 2000

16 projections/time frame

Nyquist requirement=800

Wieben et al

Stack of Stars Acquisition and HYPR Reconstruction

50x undersampling

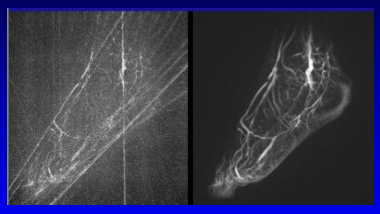

Conventional
Filtered Back
Projection

HYPR

Hybrid Time Resolved MRA

Uses a separate long acquisition for a composite image.

Composite scan can be

- Phase Contrast
- Time of Flight
- Contrast Enhanced
- Non-contrast Inflow with magnetization preparation

Contrast enhanced undersampled CE MRA frames on second injection

Eliminates the traditional tradeoff between spatial and temporal resolution

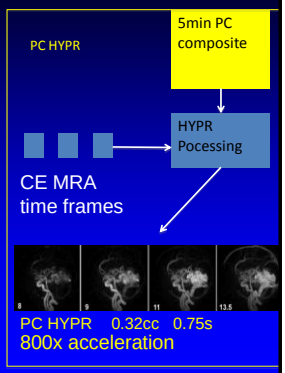

PC HYPR Flow

800 x undersampling 0.69mm isotropic 0.75 fps

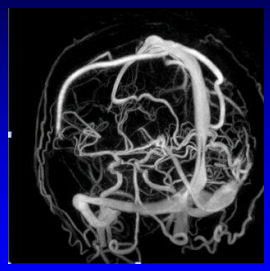

Time Resolved MRA with Near Zero Contrast Dose

PC HYPR Flow 1 cc gadolinium

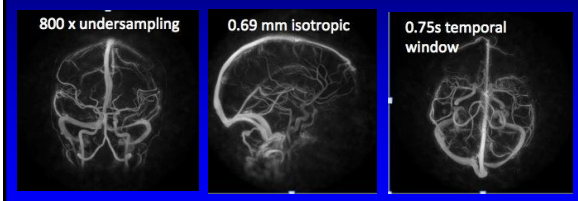

Reported Dynamic MRA Acceleration Methods

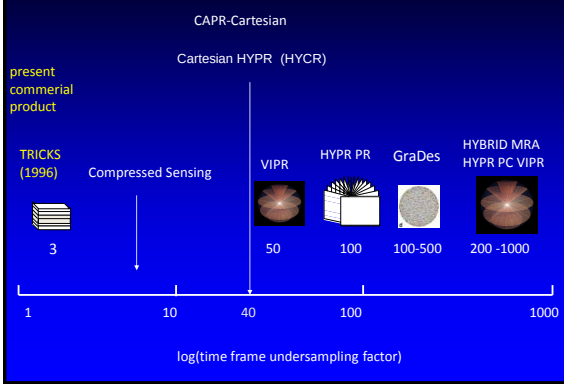

Time Resolved Angiography: A Thirty Year Circle

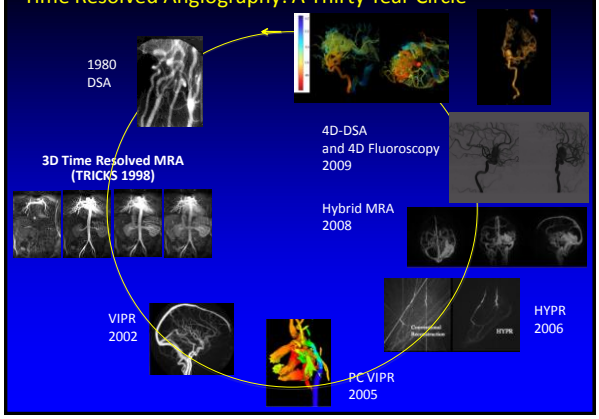

1973 Optical Engineering Article

Mistretta C.A. The use of a general description of the radiological transmission image for categorizing imaging enhancement procedures. *Optical Engineering* 13(2):134; 1974.

Five Hits

Taylor Expansion of X-ray Transmission Image

$$I(x,y,z,E,t) - I(x+\Delta x, y+\Delta y, z+\Delta z, E+\Delta E, t+\Delta t) =$$

$$(dI/dx)*\Delta x + (dI/dy)*\Delta y$$

DSA

$$+(dI/dE)*\Delta E + (dI/dt)\,\Delta t + (dI/dz)\,\Delta z$$

$$+(d^2I/dEdz)\Delta E\Delta t$$ dual energy CT

$$+(d^2I/dEdt)\,\Delta E\Delta t$$ dual energy DSA

30 yrs

$$+(d^2I/dzdt)\Delta z\Delta t$$ CTA, 4D DSA

$$+(d^3I/dEdzdt)\,\Delta E\Delta t\Delta z$$ dual energy 4D DSA

4D DSA
A New Dimension

1980 2D Time Series

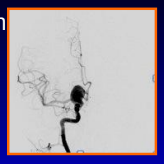

1996 3D No time

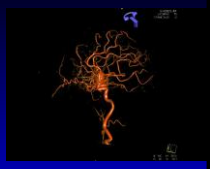

2012
4D DSA time series

32 YEARS AFTER ITS INTRODUCTION, DSA IS NOW A FULL 4D ANGIOGRAPHIC IMAGING MODALITY WITH POTENTIALLY HIGHER SPATIAL AND TEMPORAL RESOLUTION THAN MRA OR CTA.

PROVIDES ALL VIEW ANGLES AT ANY TIME

PROVIDES ALL TIMES AT ANY VIEW ANGLE

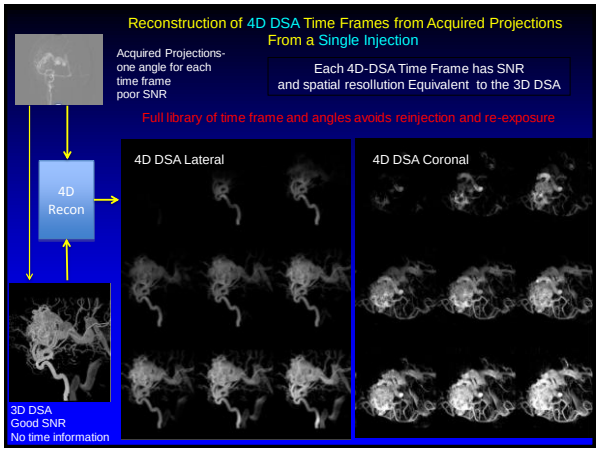

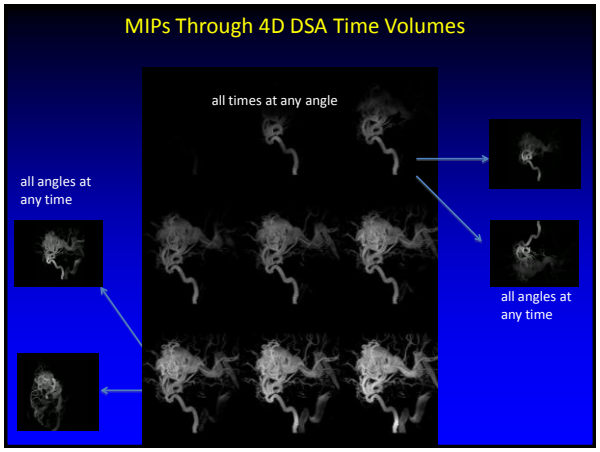

4D DSA is not an attempt to do CT with one projection.

The constraining vascular volume is already a CT reconstruction.

The single projections just deposit the temporal information into that volume.

Overlap problems are reduced using various angular search and normalization strategies.

The net result is an acceleration of 100-200 relative to what woul be possible with repeated C-arm rotation.

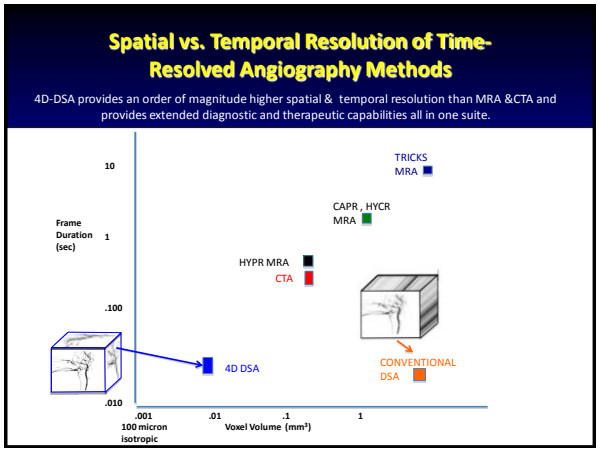

Optimal views without additional 2D DSA runs

In this example, a conventional series of 2D DSA images did not provide the optimal view of the artery emerging from the pseudoaneurysm as seen on the optimally rotated 3D DSA and additional 2D runs would have been required to properly profile the artery leading to increased X-ray and contrast dose

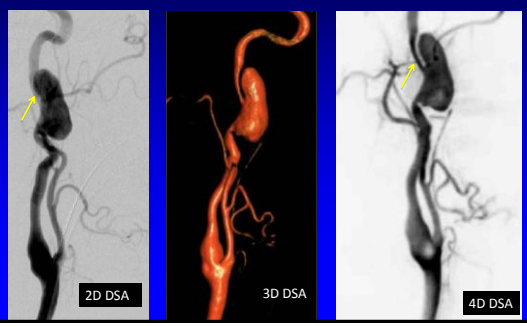

High Resolution Intravenous Angiography

The time resolved feature of 4D DSA largely eliminates the problem of arterial and venous overlap in acquisitions done with an IV injection of contrast. The red arrows follow the course of the right internal carotid artery in this canine.

Where are the ICAs and ACAs?

4D DSA clearly shows ICAs and ACAs

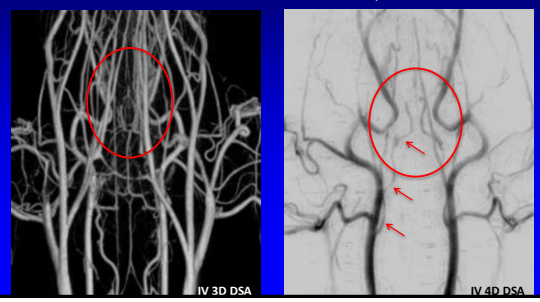

Validation of 4D DSA Flow Curves

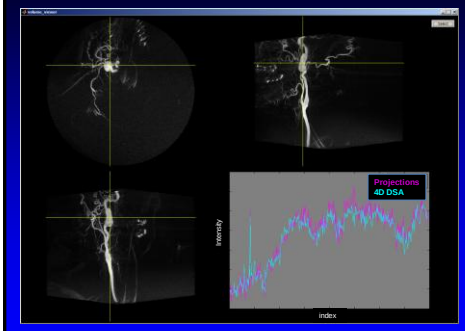

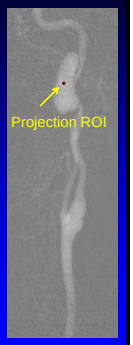

2D rotational projection

AVM Case on 4D DSA Commercial Prototype

The dynamics can be viewed at any selected angle including unobtainable angles (red icon)

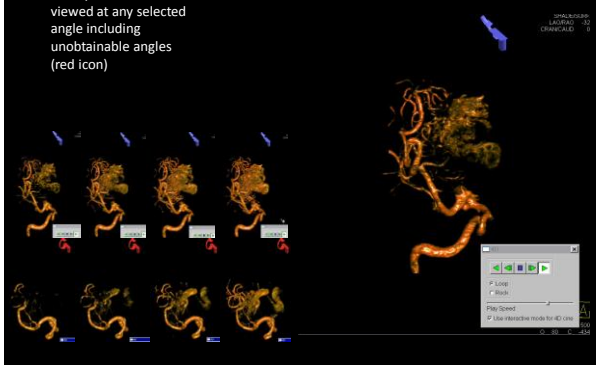

Rotatable 3D Static Temporally Encoded Display

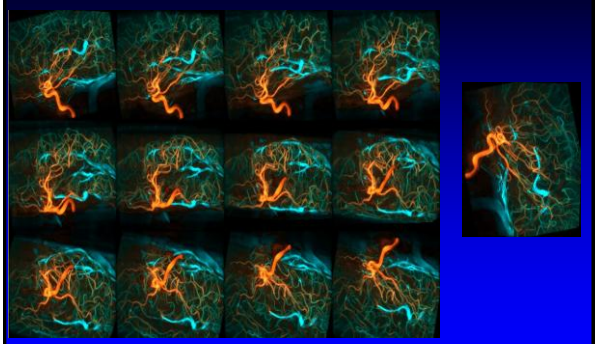

Temporal parameters available on a voxel basis and can be viewed from arbitrary angles

Quantitative Color-Coded 4D DSA (4D iFlow)

This mode displays the 4D DSA frames in color showing their time of arrival values (time-to-peak for example) as they appear. It is generated by multiplying the time-of arrival volume by binarized 4D DSA frames

It is difficult to quantitatively estimate transit times by just viewing the 4D display. With this mode the movie can be stopped and transit times between any two points can be estimated from the color scale.

Individual voxel time curves can be generated by selecting a point on the display and browsing through the planes to select a desired volume of interest.

Quantitative Color Coded 4D DSA

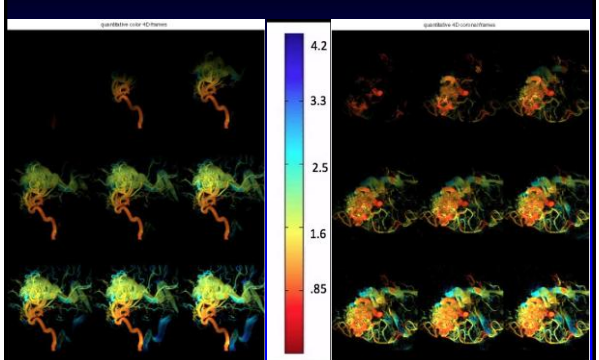

Color indicates time of arrival in seconds

4D I Flow

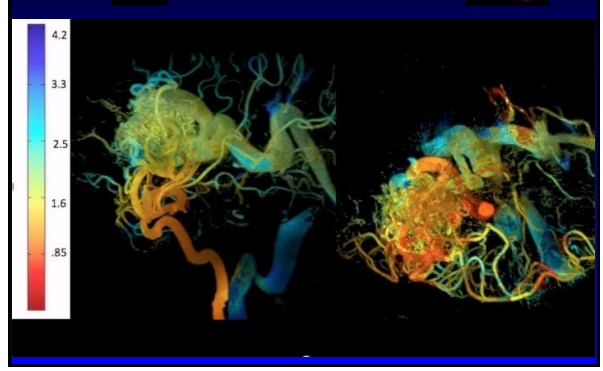

Quantitative 4D DSA Bolus tracking

In bolus tracking mode various portions of the vascular network are seen separately by multiplying the time of arrival image with a sliding window temporal mask.

Bolus Track

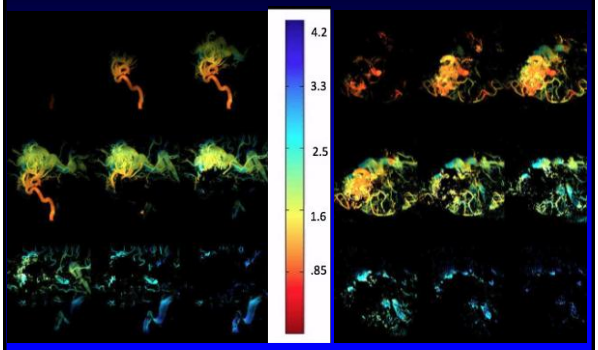

Sliding window through time of arrival image

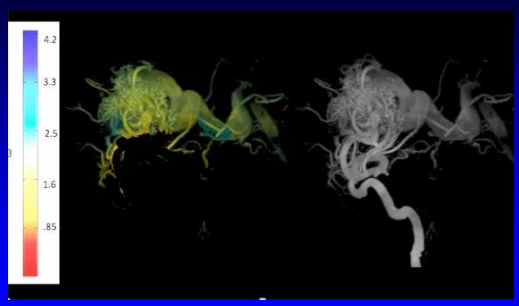

4D Modes

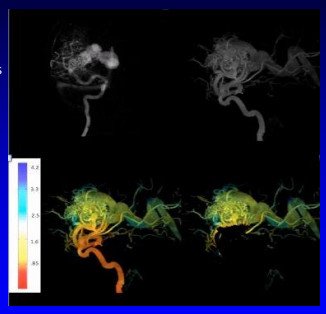

Acquired Projections

4D DSA

4D I FLOW

Bolus Track

Summary 4D DSA

1. 4D DSA provides a 3D rather than a 2D time series:
   All angles viewable at all times
   All times viewable at all angles
2. Data acquisition uses one injection, typically one or two rotations
3. The SNR of the entire rotation feeds into each 4D DSA time frame
4. Small structures seen much better due to use of 3D MIP rather than 2D projections
5. 4D DSA time frames provide a library of simplified roadmaps
6. 4D DSA increases the rate that 3D vascular volumes are produced by a factor of ~200. Instead of 1 volume in one rotation, with 4D ~200 are generated.
7. Optimal 4D views eliminate repeat DSA injections and re-exposure
8. Bolus tracking and 4D IFlow should allow better understanding of complex vascular lesions

Extension to Body Angiography

The extension of the neuro applications to body angiography has recently begun and involves potential artifacts from misregistration artifacts due to breathing and bowel peristalsis.

Acquired Projections
Low SNR

Only one angle available at each time

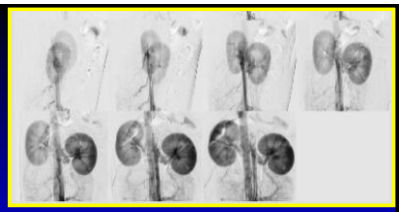

Rotating 4D DSA
Higher SNR, and small vessel detail.

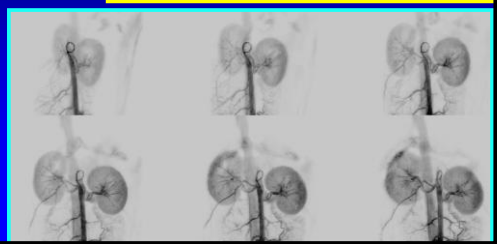

Fixed Angle 4D DSA Time Frames

High SNR - Improved small vessel detail due to MIP

Vessel contrast not diminished by averaging as in 2D DSA images.

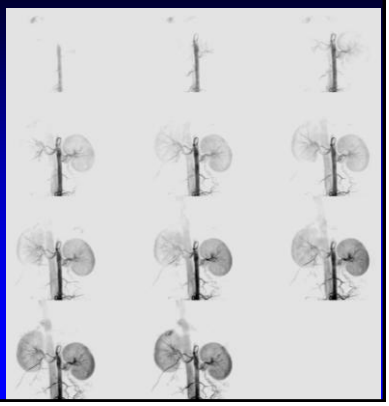

Dual Energy DSA

$I(x, y,z,E,t) - I(x + \Delta x, y + \Delta y,z + \Delta z,E + \Delta E,t + \Delta t) =$

$(dI/dx) * \Delta x + (dI/dy) * \Delta y$

$+(dI/dE) * \Delta E + (dI/dt)\, \Delta t + (dI/dz)\, \Delta z$

$+ (d^2I/dEdt)\, \Delta E \Delta t$ hybrid energy-time DSA

$+ (d^2I/dzdt) \Delta z \Delta t$ CTA, 4D DSA

$+ (d^3I/dEdzdt)\, \Delta E \Delta t \Delta z$ Dual energy 4D DSA

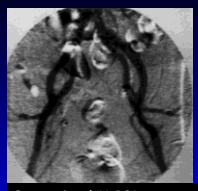

Conventional IV DSA

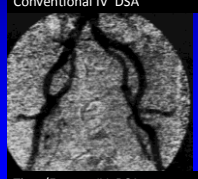

Time/Energy IV DSA

Hybrid Energy-Time ET DSA

Brody
Stanford University
1981

Conventional DSA

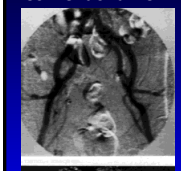

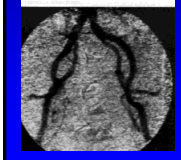

Dual Energy 3D-DSA

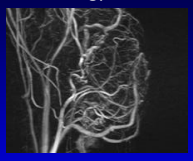

Dual Energy 4D DSA time frames

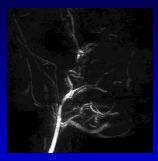

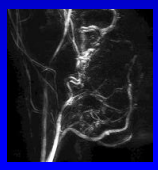

1981 Dual Energy DSA

4D Omni-Plane Fluoroscopy
No More Unobtainable Views

Using a biplane C-arm, similar techniques can be employed to permit the viewing of ongoing fluoroscopy from any direction without gantry motion.

This permits views that may not be accessible to the C-arm and can eliminate the need to send patients to surgery when adequate fluoroscopy views can not be obtained for device manipulation.

Accessible view

Unobtainable view

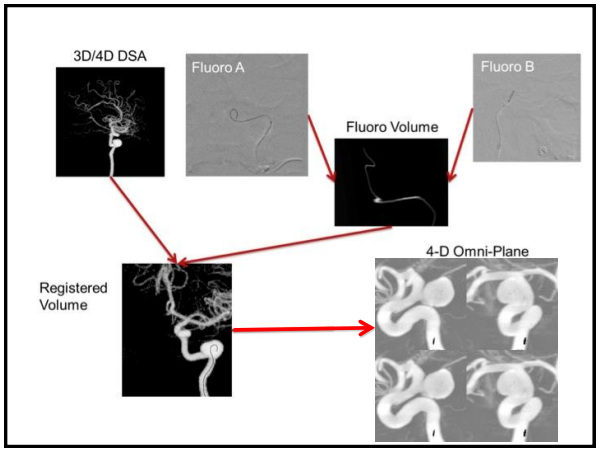

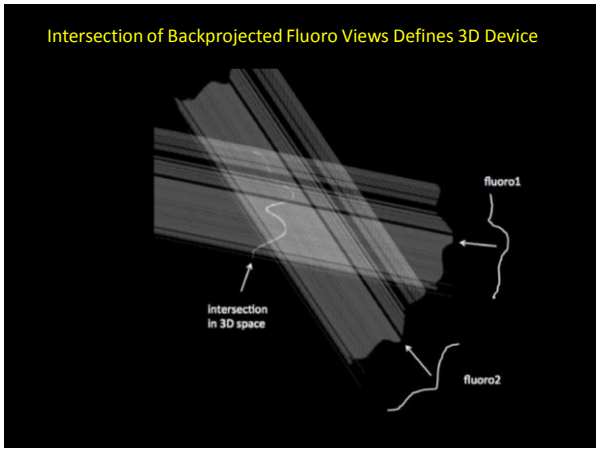

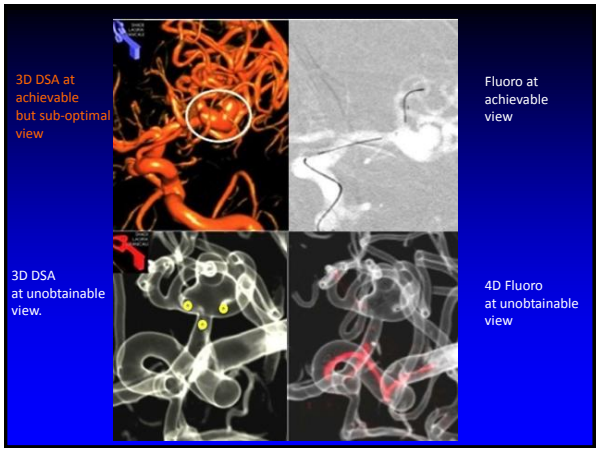

The glass pipe movie shows a device moving in the roadmap (this is the wire being removed after deployment of the first stent in one of the branches). Note that where the MCA branches have been straightened, by the wire, the wire appears to be outside of the lumen of the vessels, due to vessel displacement. This view is obtained without gantry movement.

Omni-plane viewing without gantry motion

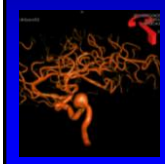

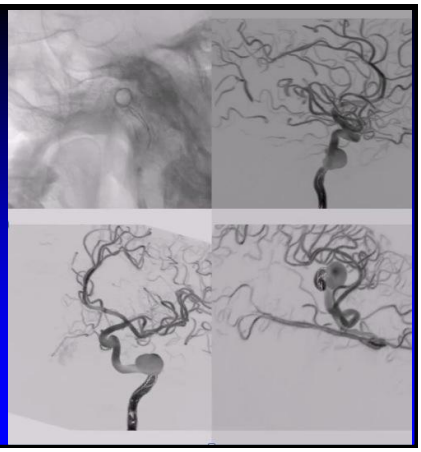

Insertion of coil into aneurysm

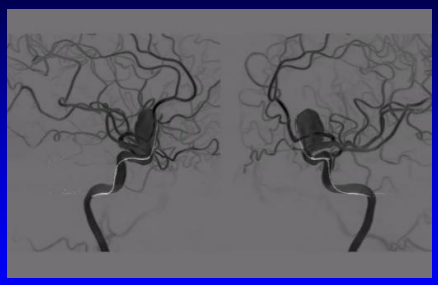

Potential For Dose Reduction with 4D Fluoroscopy

- Net procedure X-Ray & contrast dose should be reduced
  - Optimal view angles can be preselected from the 3D/4D volume and fluoroscopic views can be generated immediately at the optimal orientation without manually adjusting C-arm, table, or patient.
- New views can be generated without need for C-arm movement or needing to reset the roadmap

Impact on Interventional Radiology

The introduction of DSA in 1980 greatly facilitated the development of interventional radiology.

The availability of 4D DSA and 4D fluoroscopy will lead to the ability to complete more interventions with greater safety ar reduced contrast and radiation dose.

Radiologists will conceive of new applications and improve quantification of results with these new tools.

Conclusions

- 4D-DSA adds value to the ability to visualize complex vascular abnormalities
- Decreasing the need for multiple 2D DSA acquisitions allows the possibility of procedures performed with less contrast and lower radiation dose
- All angles, all views capability of 4D fluoroscopy allows for the possibility of successful endovascular treatment of lesions that otherwise would require open surgery
- Application of reconstruction with undersampled data sets and constrained reconstruction in x-ray DSA has completed the transition to a full 4D modality which should expand the role of DSA in diagnosis and intervention.

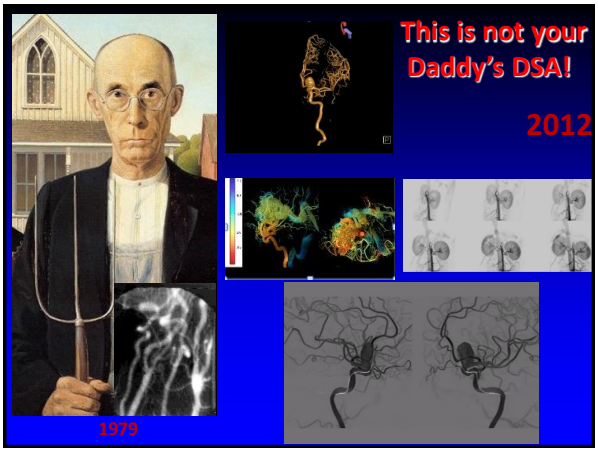

Impact of Sub-Nyquist Acquisition and Constrained Reconstruction in Other Medical Imaging Areas

The principles that have led to the development of 4D DSA have begun to be applied in diverse areas of medical imaging

Noise Reduction and Image Quality Improvement of Low Dose and Ultra Low Dose Brain Perfusion CT by HYPR-LR

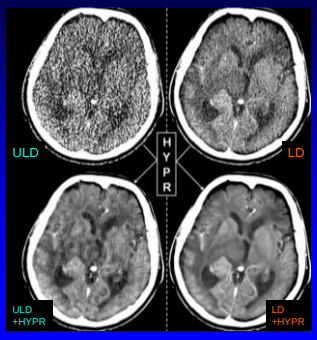

Krissak R, Mistretta CA, Henzler T, Chatzikonstantinou A, Scharf J, et al. (2011) Processing. PLoS ONE 6(2): e17098.doi:10.1371/ journal.pone.0017098

LD = 80kVp 200mA
ULD = 80 kVp 30 mA

Denoising of Dynamic Pet Series

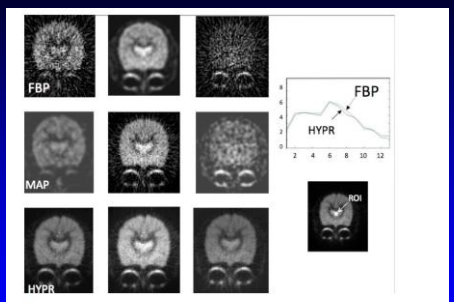

Figure 22 Comparison time frames form a PET series reconstructed with FBP, MAP and HYPR. Also shown are the time-activity curves from the region of interest indicated. Images courtesy of Brad Christian.

Christian BT, Vandehey NT, Floberg J, Mistretta CA. Dynamic PET denoising with HYPR Processing. Journal of Nuclear Medicine

Doppler Ultrasound of Middle Cerebral Artery Through The Skull

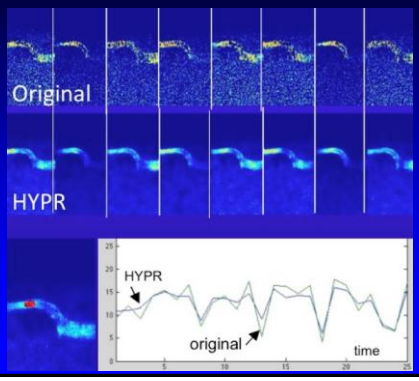

Ultrashort TE Imaging of Bone

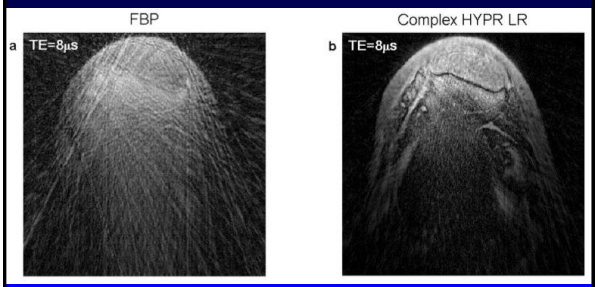

Wang K, O'Halloran R, Fain S, Kecskemeti S, Wieben O, Johnson K, Mistretta C, and Du, J, MR Spectroscopic Imaging of Short T2 Tissue Using Complex Division (CD) HYPR-LR Reconstruction, Poster 3148, ISMRM, Toronto, 2008.

Acknowledgements

MRA Accelerated Neuoro-MRA Using Compressed Sensing an Constrained Reconstruction, NIH 5R01NS066982-03

Support from GE Healthcare

DSA 4D DSA and 4D Fluoroscopy: Validation of Diagnostic and Therapeutic Capabilities" NIH 1 R01 HL116567-01

Support from Siemens Imaging Solutions