





## Introduction

- Respiration can induce thoracic and abdominal motion.
- Both organs and tumors move with respiration.
- In radiation oncology, to provide sufficient dose to the tumor while reduce radiation to organs-at-risk, knowledge of organ and tumor motion is essential.





## Introduction

- 4D imaging can be used to track motion.
- 4DCT has been used in radiotherapy motion management.

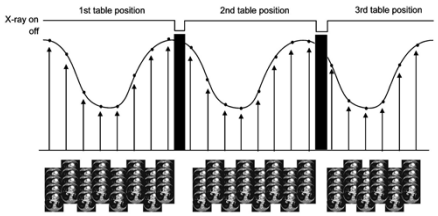


Pan et al. Med Phys 2004;31(2):333-340





## Introduction

- Challenges in 4DCT – lack of tissue and tumor contrast.
- May not be a huge issue for lung cancer.
- It is a real problem for abdominal cancer.





## Introduction

- Improving tissue and tumor contrast with MRI.

## Introduction

- Improving tissue and tumor contrast with MRI.

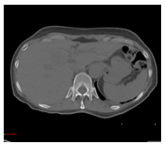

CT





## Introduction

- Improving tissue and tumor contrast with MRI.

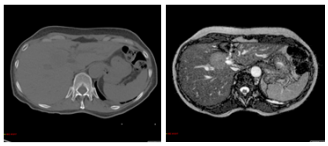

CT MRI-bSSFP





## Introduction

- Improving tissue and tumor contrast with MRI.

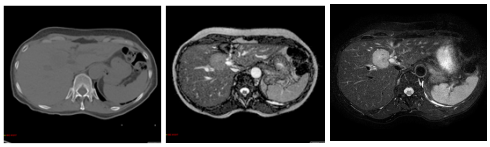

CT MRI-bSSFP MRI-$T_2$





## 4DMRI

- Typical 4DMRI image acquisition scheme
  - 2D+t+1D = 4D
  - 3D+t = 4D

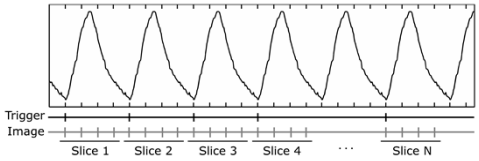






## Compatible MRI sequences

- Images at different respiratory phases have to be acquired within one respiratory cycle.
- Fast imaging techniques are needed.
- Typical pulse sequences used in 4DMRI
  - Spoiled gradient echo (FLASH, SPGR or T1-FFE)
  - Balanced SSFP (TrueFISP, FIESTA or bFFE)





## 4DMRI

- 2D+t+1D
  - Temporal resolution: ~4 frames/second
  - Spatial resoluiton: ~2×2×8mm
- 3D+t
  - Temporal resolution: <1 frame/second
  - Spatial resolution: ~ 3×3×4mm

## Spoiled gradient echo

- Sequence diagram

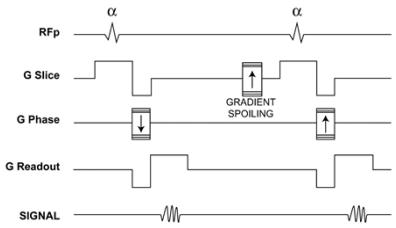


Chavhan G B et al. Radiographics 2008;28:1147-1160





## Spoiled gradient echo

- Representative images

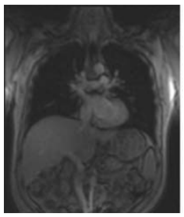

Fabel et al. Eur. Radiol. 2009;19:391-399





## Balanced SSFP

- Sequence diagram

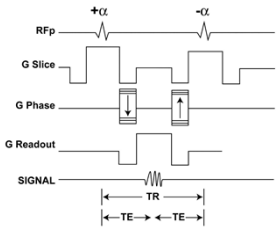


Chavhan G B et al. Radiographics 2008;28:1147-1160





## Balanced SSFP

- Representative images

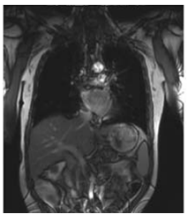

Fabel et al. Eur. Radiol. 2009;19:391-399





## Guided 4DMRI acquisition

- Guidance
  - No guidance
  - Prospective
  - Retrospective





## 4DMRI – no guidance

- 2D Balanced SSFP

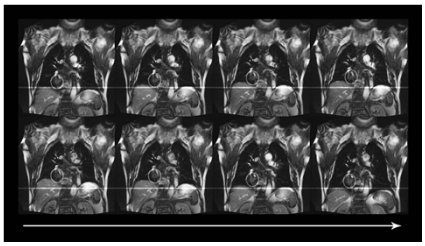

Biederer et al. J Magn Reson Imaging 2010;32:1388-1397

## 4DMRI – no guidance

- 3D Spoiled gradient echo

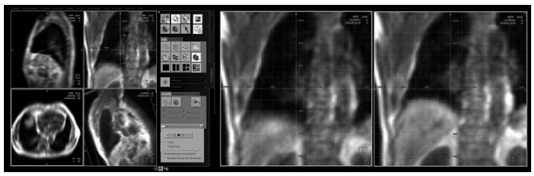

Biederer et al. J Magn Reson Imaging 2010;32:1388-1397





## Prospectively guided 4DMRI

- Need surrogate: internal or external.
- Typical internal surrogate is liver-lung boundary

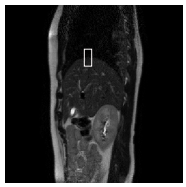





## Prospectively guided 4DMRI

- Acquisition scheme

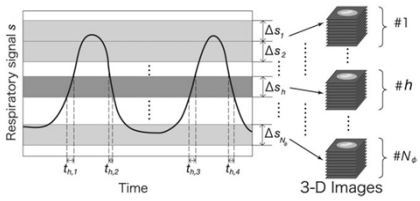


Tokuda J et al. Magn Reson in Med 2008;59:1051-1061





## Prospectively guided 4DMRI

- Results

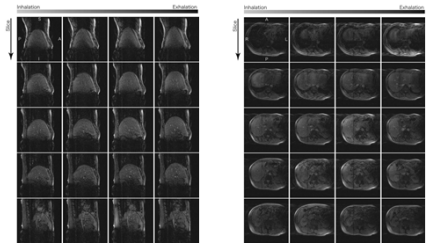

Tokuda J et al. Magn Reson in Med 2008;59:1051-1061





## Prospectively guided 4DMRI

- Respiratory amplitude guided 4DMRI

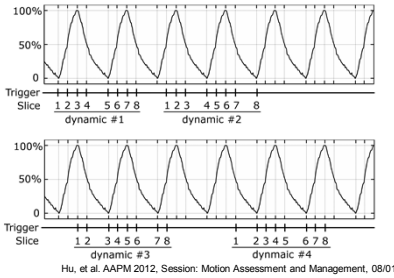


Hu, et al. AAPM 2012, Session: Motion Assessment and Management, 08/01, 5:00pm, 213CD





## Prospectively guided 4DMRI

- Images at different respiratory states

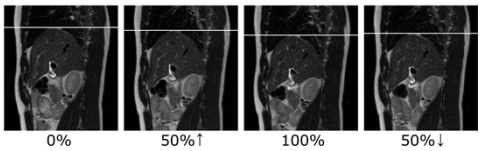

0% 50%↑ 100% 50%↓

## Prospectively guided 4DMRI

- Images in reconstructed view

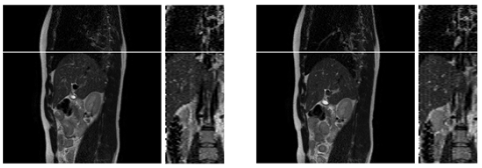

0% 100%





## Prospectively guided 4DMRI

- Robust to breathing irregularities

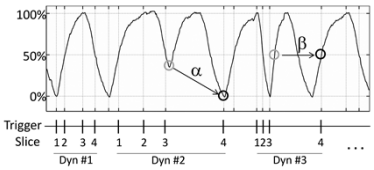






## Retrospective guided 4DMRI

- Retrospective sorting using external surrogate

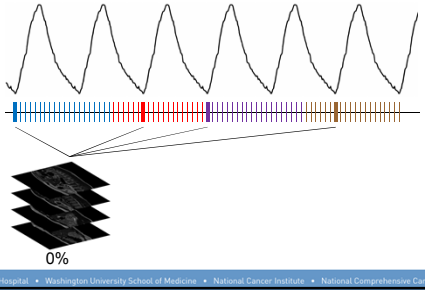

0%





## Retrospective guided 4DMRI

- Retrospective sorting using external surrogate

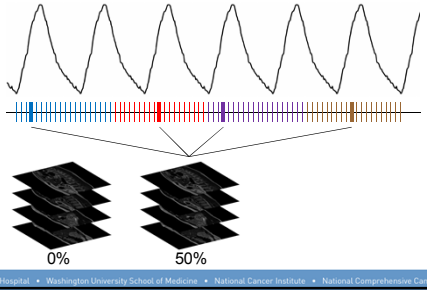

0% 50%





## Retrospective guided 4DMRI

- Retrospective sorting using external surrogate

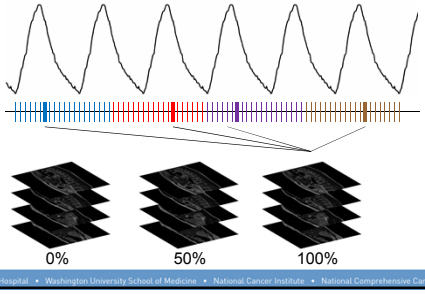

0% 50% 100%





## Retrospective guided 4DMRI

- Retrospective sorting using internal surrogate

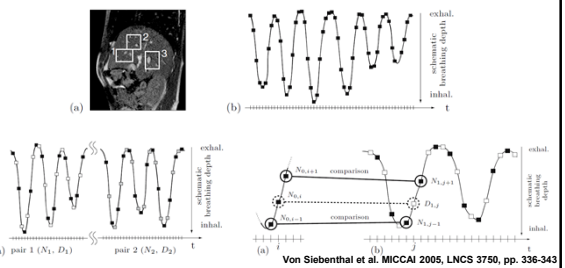


Von Siebenthal et al. MICCAI 2005, LNCS 3750, pp. 336-343

## Conclusion

- A variety of techniques have been developed to acquire 4DMRI.
- 4DMRI is still limited by spatial resolution and temporal resolution compared to 4DCT.
- Future studies should be focused on improving respiratory sorting robustness and accuracy, tumor-tissue contrast, image quality, spatial resolution and temporal resolution.





## Acknowledgements


- Washington University in St. Louis
  - Shelton Caruthers, Ph.D.
  - Parag Parikh, M.D.
  - Sasa Mutic, Ph.D.
  - Dennis Hallahan, M.D.
  - Joseph Ackerman, Ph.D.
  - Joel Garbow, Ph.D.
- University of California, Los Angeles
  - Daniel Low, Ph.D.






www.siteman.wustl.edu