UMC Utrecht

MRI RT Guidance

MR-guided Radiation Therapy

Jan Lagendijk

Universitair Medisch Centrum Utrecht

Central concept is **uncertainty**

Courtesy Dirk Verellen

Nature Reviews | Cancer

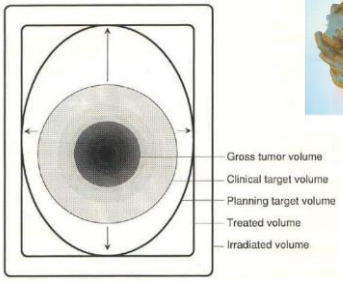

ICRU-50

Tumour control probability

- Large GTV needs higher dose compared to small GTV
- GTV needs higher dose compared to CTV

- Infiltrations - 50 Gy
- GTV - 65 Gy
- Large GTV - 80 Gy

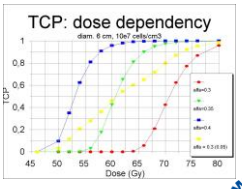

Present indications Radiotherapy

	distant	CTV	GTV
Chemo	++	+	-
RT	-	++	-/+
Surgery	--	-/+	+

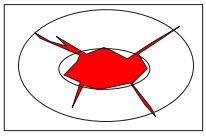

Based on: TCP models
clinical experience

Present indications Radiotherapy

	distant	CTV	GTV
Chemo	++	+	-
RT	-	++	-/+
Surgery	--	-/+	+

Best treatment combination

Based on: TCP models
clinical experience

Development MRI guided RT

	distant	CTV	GTV
Chemo	++	+	-
RT	-	++	++
Surgery	--	-/+	+

Introduction on line MRI soft tissue guidance

Development MRI guided RT

	distant	CTV	GTV
Chemo	++	+	-
RT	-	++	++
Surgery	--	-/+	+

Introduction on line MRI soft tissue guidance

- Better local control
- Less surgery

Improve local control by tailored dose escalation

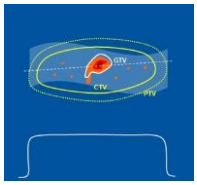

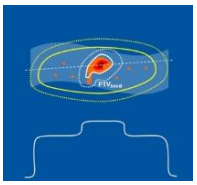

Present step: SIB for GTV. GTV gets its own PTV

Improve local control by tailored dose escalation

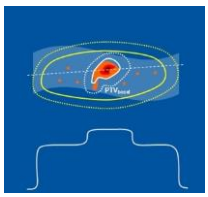

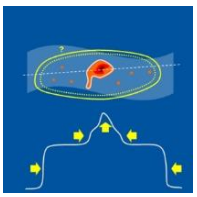

Next step: Boosting GTV while keeping the CTV uniform dose

Improve local control by tailored dose escalation

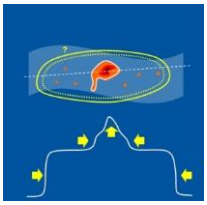

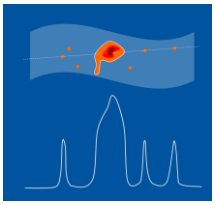

Last step: tailoring the full dose distribution

Uncertainty kills dose painting

Vision

- To bring such a certainty in the treatment process that tailoring the dose distribution becomes possible
- By such improving local cancer therapy
- Making local therapy non-invasive
- Better control with less toxicity

Seeing helps: hit the sailing boat

Success stories RT thanks to better imaging and a tailored dose distribution

Sites
- Brachytherapy cervix (MRI)
- Prostate (fiducial gold markers)
- Lung peripheral (conebeam CT contrast)

Results
- Higher GTV dose
- Good local control
- Hypo fractionation
- Lower toxicity
- Lower integral dose

Failures RT

- Esophagus
- Pancreas
- Kidney
- Liver
- Rectal
- Colon
- Stomach

Troubles RT

- Bladder
- Breast
- Larynx
- Lymph nodes

What is needed

- High quality imaging at the moment of treatment
- Certainty

Lung, irregular breathing (sBFFE)

Courtesy Astrid van Lier

Cervix

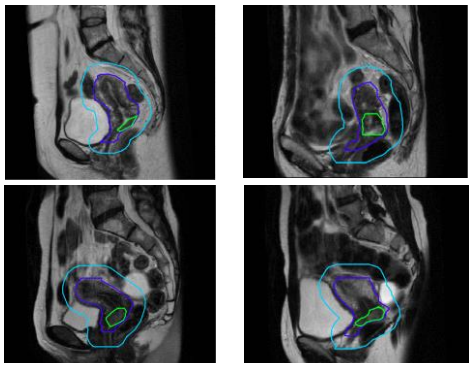

Intra fraction motion in the pelvis
2D monitoring (2Hz)

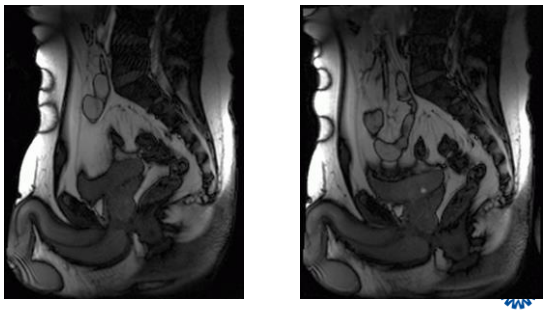

Visualisation oesophagus tumour

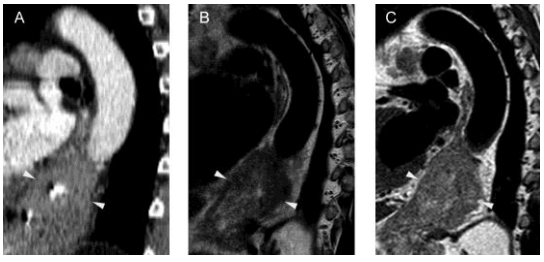

CT | No triggering + free breathing | Triggering + breath hold

Courtesy Astrid van Lier

T2w MRI tumour oesophagus

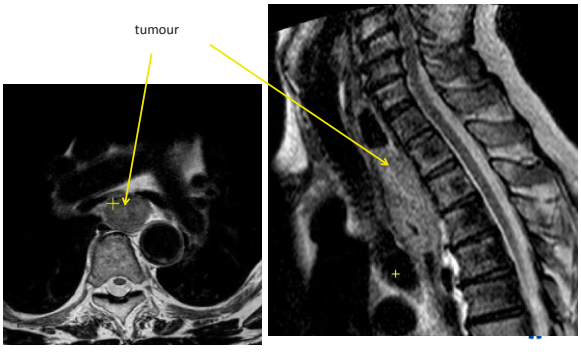

T2w MRI tumour oesophagus

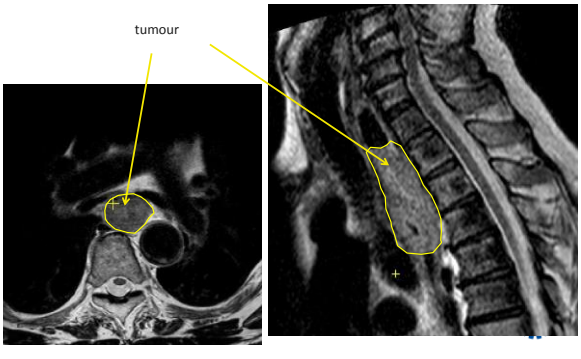

Validation of larynx MR

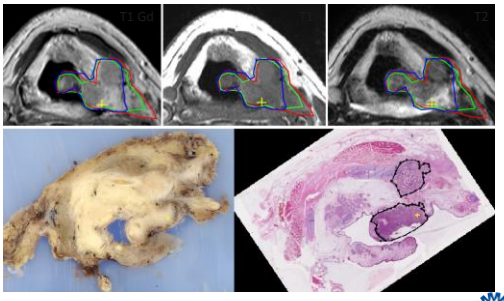

L Jager, CPJ Raaijmakers

Small field targeting larynx

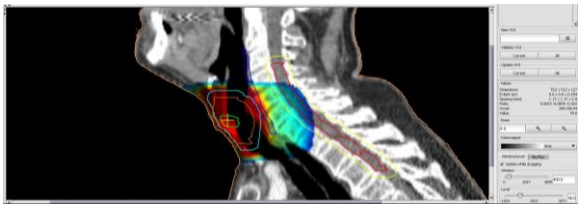

Small field targeting larynx

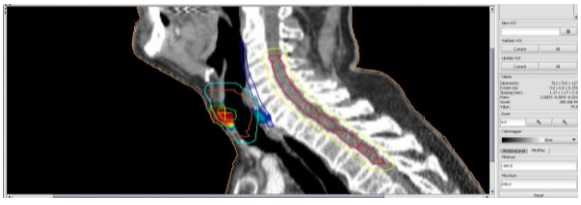

MRI offers great soft-tissue contrast Rectum

The rectum, anatomy on MRI, from inside to outside:

- Lumen
- Three rectal wall layers:
  - Mucosal layer
  - Submucosal Layer
  - Muscle layer
- Mesorectal fat
- Mesorectal fascie

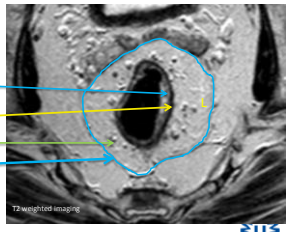

Breathing related motion

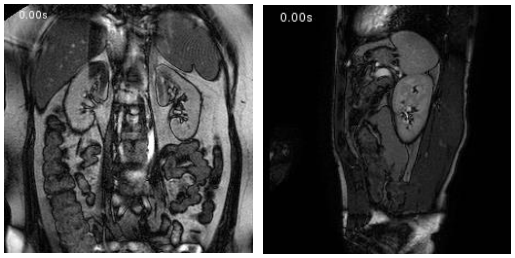

irregular breathing von Hippel Lindau kidney tumour

Breathing related motion

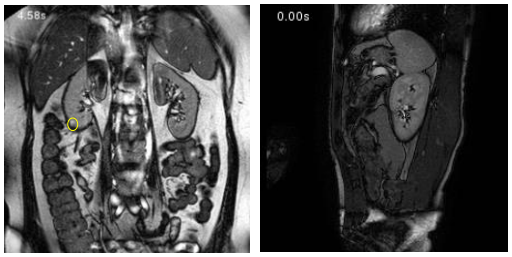

irregular breathing von Hippel Lindau kidney tumour

Stam et al. Phys Med Biol. 2013, 2235-45

New 3D T2-FFE sequence with unique visualization lymph nodes breast cancer patients

- 3D T2-FFE with some intrinsic diffusion weighting, fat suppression and black blood imaging
- Resolution 0.7x0.7x1 mm
- Geometrically correct, targeting 1.5 T MRL

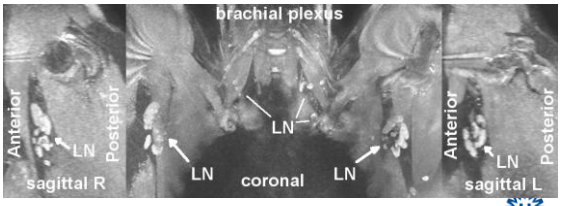

3D T2FFE image quality

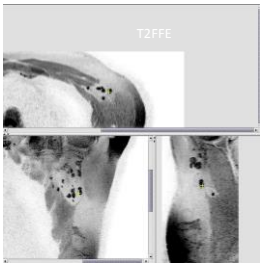

Next step is finding lymph vessels to define which nodes are related to arm only

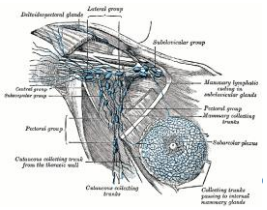

Stereotactic boost individual lymph nodes

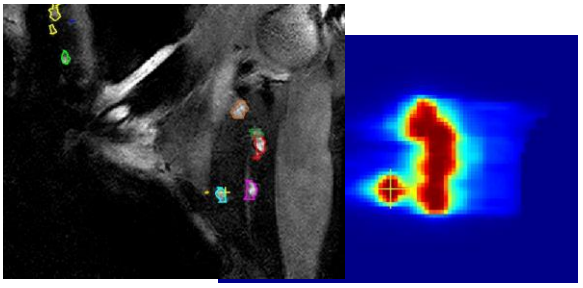

Courtesy Tristan van Heist

Lymph nodes visualization H&N

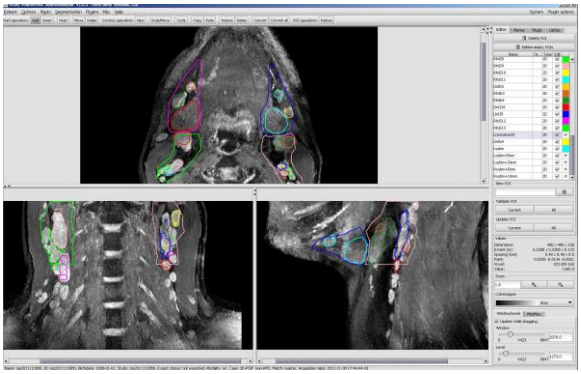

Lymph nodes T2-FFE MRI Head and Neck

Courtesy: Marielle Philippens

Stereotactic boost mediastinal lymph nodes

PET

DWI

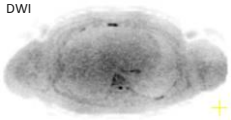

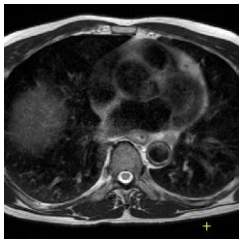

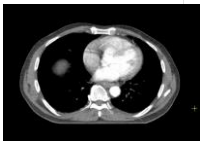

Courtesy Astrid van Lier

Stereotactic boost mediastinal lymph nodes

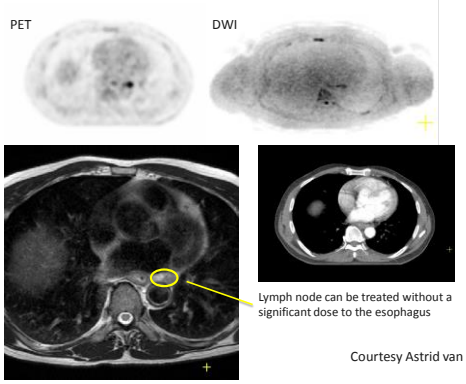

Courtesy Astrid van Lier

Development of the ultimate MRI targeting system

Diagnostic quality MRI
Stereotactic targeting accuracy 0.5-1 mm
On line/intrafraction/breathing
Tracking organs movements/shape changes
Therapy plan update continuously
Treatment response assessment

High dose rate
Good IMRT properties (penumbra, scatter, transmission)
Fast MLC

UMCU solution: Integrating a Philips MRI scanner with a Elekta radiotherapy accelerator

1.5T 70 cm bore Philips Ingenia

Bringing the MRI linac concept to clinic

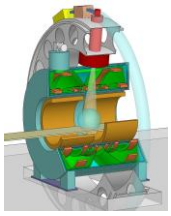

Simulation process

+

MRI simulator

MRI accelerator

Simulation process

- Visualization
- Characterization
- Mobility

- Preparation on-line treatment planning process

Simulation process

- Characterization mobility

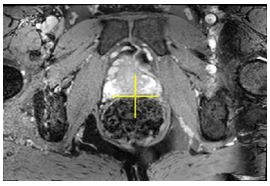



Liver, irregular breathing

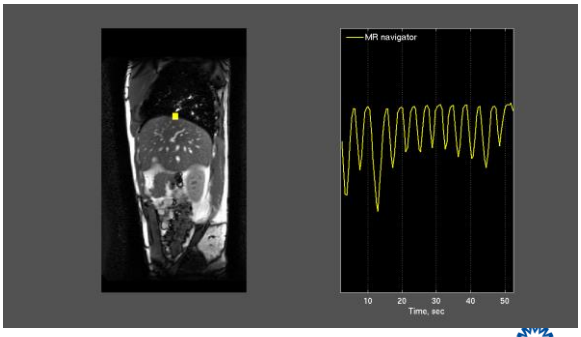

Courtesy Anna Andreychenko

Pancreas: undersampled radial balanced SSFP

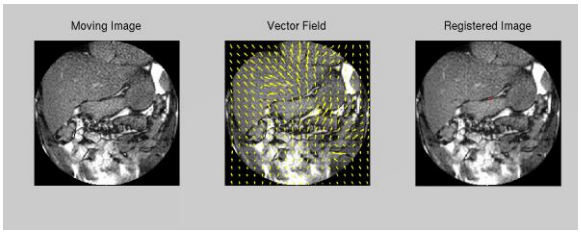

Thanks: Baudouin Denis de Senneville, UMCU HIFU Group

Motion management in a patient

- No 1D motion, but more complex
- Requires (ideally) 4D imaging
- Alternative:
  - multiple 2D slices and 1D pencil-beam navigators to capture main modes of motion
  - Acquisition strategies, under-sampling eg in combination with radial read-out

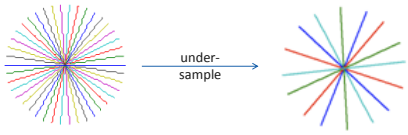

Courtesy Rob Tijssen and Sjoerd Crijns

Radial under-sampling

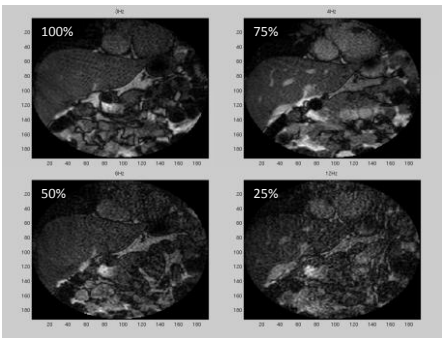

MRL treatment planning (MRLTP):

Conventional treatment planning procedures are sequential

Treatment planning process takes typically between two and four hours

MRL treatment planning (MRLTP):

Characterization anatomy and mobility

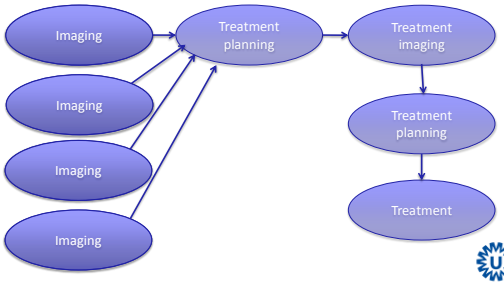

MRL treatment planning (MRLTP):

MRL treatment planning procedures are feed back loops (there is no table control)

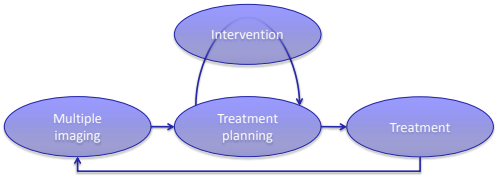

Has to become a real time process

MRL treatment planning (MRLTP): Fast IMRT planning system

- System requires on-line treatment planning
- No table related positioning

MRLTP:

- Beamlets: GPUMCD
- ITP: FIDO (From Goldman et al. 2009)
- DA sequencing (Cao et al., 2006)

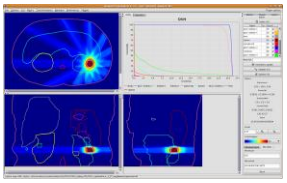

Kidney IMRT plan in 15 sec.
(1 GTX480 per beam)

Bol et al., PMB, 2012, 57, 1375-85

VCS of phantom and cervix case



(a) Phantom case (b) Cervix case

48 translations in x,y,z direction: 1,2,3,5,8,13,21,34 mm
42 rotations around x,y,z axis: 1,2,3,5,8,13,21 degrees

Bol et al., PMB, 2013, 58, 2989-3000

VCS of phantom and cervix case

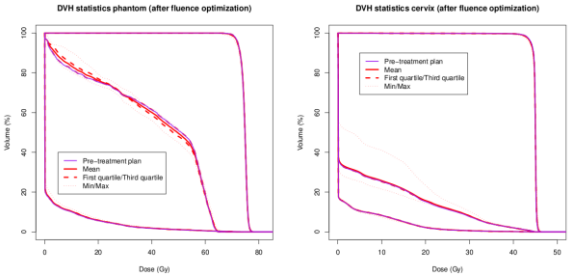

Radiotherapy UMC Utrecht goes MRI

- Tumour characterization
- MRI simulation: delineation
- MRI guidance
  - MRI treatment guidance external beam
  - MRI guided brachytherapy
  - MRI guided HIFU
  - MRI guided protons
  - MRI guided radioembolization
- MRI treatment response assessment

7 MRI systems for therapy

- 3x MRI linac
- 1x 1.5 T and 1x 3.0 T simulator
- 1x 1.5T HIFU
- 1x 1.5T brachytherapy

Team MRL



Acknowledgement

Physics Team MRL UMCU

- Anna Andreychenko
- Bram van Asselen
- Nico van den Berg
- Hans de Boer
- Alex Bhogal
- Gijsbert Bol
- Maxence Borot
- Sjoerd Crijns
- Markus Glitzner
- Sophie Heethuis
- Tristan van Heijst
- Stan Hoogcarspel
- Jean-Paul Kleijnen
- Charis Kontaxis
- Astrid de Leeuw
- Astrid van Lier
- Hans Ligtenberg
- Stefano Mandija
- Gert Meijer
- Rien Moerland
- Christel Nomden
- Marielle Philippens
- Mathew Restivo
- Niels Raaijmakers
- Bas Raaymakers
- Rob Tijssen
- Tim Schakel
- Yulia Shcherbakova
- Frank Simonis
- Kimmy Smit
- Bjorn Stemkens
- Jochem Wolthaus
- Cornel Zachiu

Clinical Team MRL UMCU

- Desiree van den Bongard
- Maarten Burbach
- Ramona Charaghvandi
- Joris Hartman
- Mariska den Hartogh
- Hanne Heerkens
- Martijn Intven
- Lisanne Jager
- Linda Kerkmeijer
- Irene Lips
- Juliette van Loon
- Metha Maenhout
- Max Peters
- Onne Reerink
- Peter van Rossum
- Ina Schulz
- Chris Terhaard
- Joanne van der Velden
- Marco van Vulpen
- Danny Young-Afat