THE UNIVERSITY OF TEXAS
MD Anderson Cancer Center
Making Cancer History®

Brachy: Basics to Advancements

Image-Guided Prostate Brachytherapy:
A US, MR, and CT-Based LDR Workflow

2022 AAPM Spring Clinical Meeting

Samantha J. Simiele, PhD, DABR
Assistant Professor
sjsimiele@mdanderson.org

COI statement

- None

Disclaimer

- The mention of specific vendors or products used in our clinic is not meant to provide endorsement
- The information included in this presentation is provided for educational purposes and is not meant to represent guidelines or recommendations

Learning objectives

1. Understand the roles that various imaging modalities may have in a low dose rate prostate seed implant program
2. Recognize some of the benefits of MRI-based planning over traditional CT or US-based planning
3. Describe considerations for implementing MRI-based treatment planning

Program overview

- Prostate seed implant program started in mid-90s
- First patient treated using MRI-planning in December 2013
  - Utilize three different sources
  - Monotherapy, boost, and salvage cases
- Utilize various imaging modalities
  - **MRI: Diagnosis, volume study, pubic arch interference, pre-planning, post-planning**
  - TRUS: Intraoperative image guidance
  - CT: Post-implant assessment

Isotope	Half-life (d)	Dose rate (cGy/hr)	Energy (keV)	Time of 90% decay (d)	Rx (Gy)
^{125}I	59.4	7	28	197	144
^{103}Pd	17	21	21	56	125
^{131}Cs	9.7	32	30	33	115

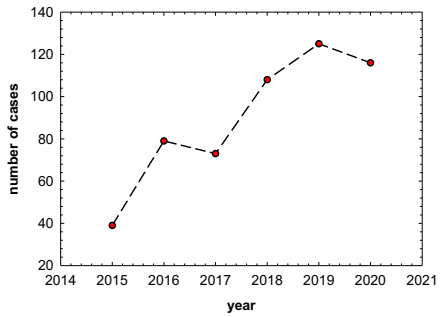

Advantages of MRI-based planning

1. Superior soft tissue contrast
   - Visualization of intraprostatic lesions[1]
   - Improved contour accuracy[2]
     - Targets
     - Organs at risk (OARs)
2. No imaging dose
3. Potential reduction in cost to patient[3]

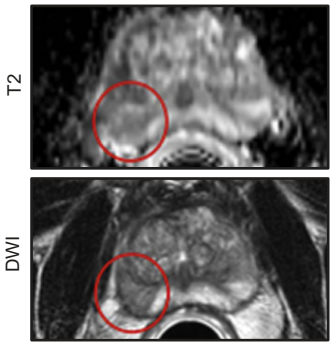

1. Frank et al., Brachytherapy 16 (2017) 672 – 678
2. Rasch et al., IJROBP 43 (1999) 57 – 66
3. Thaker et al., Brachytherapy 21 (2022) 49-54

Workflow overview

1. Initial MRI
2. Pre-planning
3. Physics and QA
4. Implant
5. Post-procedure

Initial MR → Pre-Planning → Physics & QA → Implant → Post-procedure

Initial MRI Scan

- Single scan acquired 2 – 4 weeks prior to implant
- Patient scanned in feet first supine orientation
- Axial 3D T2 sequence
- Multi-purpose
  - Diagnosis
  - Volume study
  - Pubic arch interference (PAI) assessment
  - Pre-planning

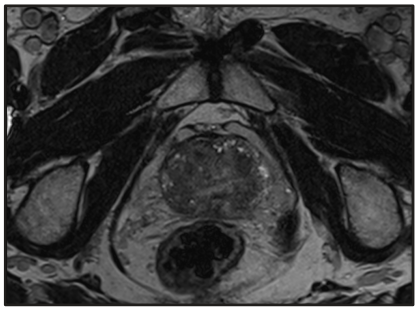

Axial 3D T2

Initial MR → Pre-Planning → Physics & QA → Implant → Post-procedure

Initial MRI Scan

- Pubic arch interference assessment
- Traditionally performed using TRUS with patient in dorsal lithotomy position
- MRI and CT method[1]
  - Contour prostate
  - Project contour for the largest slice at mid-gland onto pubic bones
  - Evaluate overlap

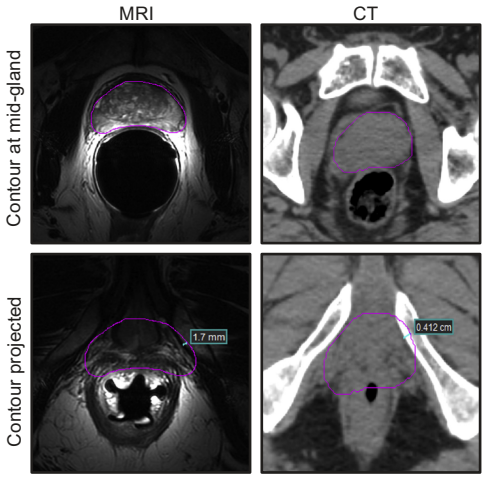

1. Martin et al., Brachytherapy 16 (2017) 728 - 733

Initial MR | **Pre-Planning** | Physics & QA | Implant | Post-procedure

Contouring

- Import MRI into treatment planning software
- Superior soft-tissue contrast of MRI improves contouring accuracy
- Contour
  - Target structures: (1) Prostate, (2) PTV, (3) Seminal vesicles
  - Organs at risk: (1) Bladder, (2) External urinary sphincter (EUS), (3) Rectum

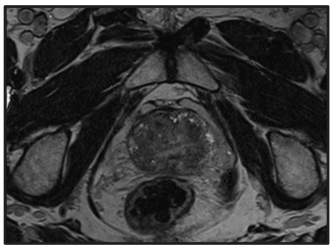

Axial 3D T2

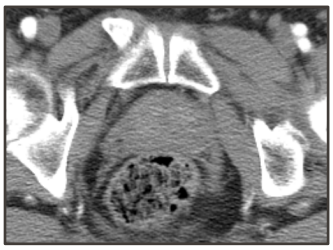

CT scan

Initial MR | **Pre-Planning** | Physics & QA | Implant | Post-procedure

Contouring

- Import MRI into treatment planning software
- Superior soft-tissue contrast of MRI improves contouring accuracy
- Contour
  - Target structures: (1) Prostate, (2) PTV, (3) Seminal vesicles
  - Organs at risk: (1) Bladder, (2) External urinary sphincter (EUS), (3) Rectum

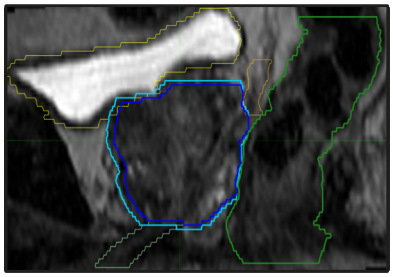

Initial MR | **Pre-Planning** | Physics & QA | Implant | Post-procedure

Virtual simulation

- Accounts for displacement of the prostatic apex
  - From the legs-down position during simulation
  - To the lithotomy position during the implant
- Planning system has several virtual TRUS probes available
  - Align the probe with the posterior surface of the prostate
  - Angle the probe approximately 8 degrees[1]
  - Angle was determined from the first 20 patients treated
- Re-slice the MRI scan to 5 mm slices

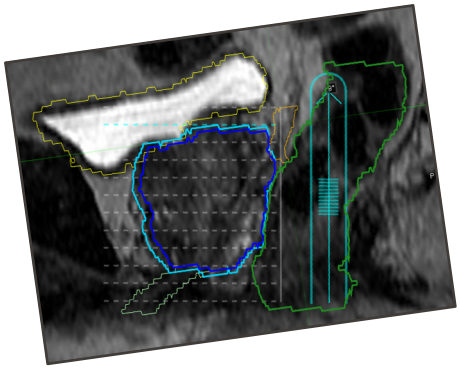

1. Blanchard et al., Brachytherapy 16 (2017) 734-742

Initial MR | **Pre-Planning** | Physics & QA | Implant | Post-procedure

Planning technique

- Planning technique is isotope-dependent
  - ^{125}I: Modified-peripheral loading
  - ^{103}Pd: Modified-uniform loading
  - ^{131}Cs: Peripheral loading
- Stranded seeds
  - Seed, spacer, seed
  - Spacer is a C4 imaging marker that is visible on MRI
- Planning objectives are isotope-dependent
  - Evaluate PTV coverage during pre-planning
  - Evaluate Prostate coverage during post-planning

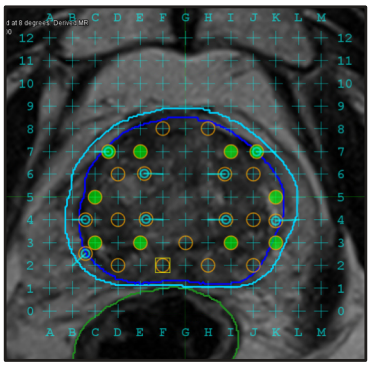

^{125}I monotherapy treatment plan

Initial MR | **Pre-Planning** | Physics & QA | Implant | Post-procedure

Planning technique

- Planning technique is isotope-dependent
  - ^{125}I: Modified-peripheral loading
  - ^{103}Pd: Modified-uniform loading
  - ^{131}Cs: Peripheral loading
- Reducing toxicities[1]
  - Dose received by the EUS is correlated with urinary toxicity
  - Proposed dose constraints for this structure
  - EUS V200 < 0.04 cm^3

Volume		^{125}I	^{103}Pd	^{131}Cs
PTV (pre-plan)	D90	≥ 100%	≥ 100%	≥ 100%
	V100	≥ 95%	≥ 95%	≥ 95%
	V150	≤ 60%	≤ 70%	≤ 50%
	V200	≤ 20%	≤ 40%	≤ 15%
Prostate (post-plan)	D90	≥ 100%	≥ 100%	≥ 90%
	V100	≥ 95%	≥ 95%	≥ 95%
	V150	≤ 60%	≤ 70%	≤ 50%
	V200	≤ 20%	≤ 40%	≤ 15%
Rectum	V100	≤ 1 cm^3	≤ 1 cm^3	≤ 0.5 cm^3
EUS	V200	≤ 0.04 cm^3	≤ 0.04 cm^3	≤ 0.05 cm^3

* Dose objectives are nominal and may be modified at physician discretion

1. Boyce-Fappiano et al., Brachytherapy 19 (2020) 574-583

Initial MR | **Pre-Planning** | Physics & QA | Implant | Post-procedure

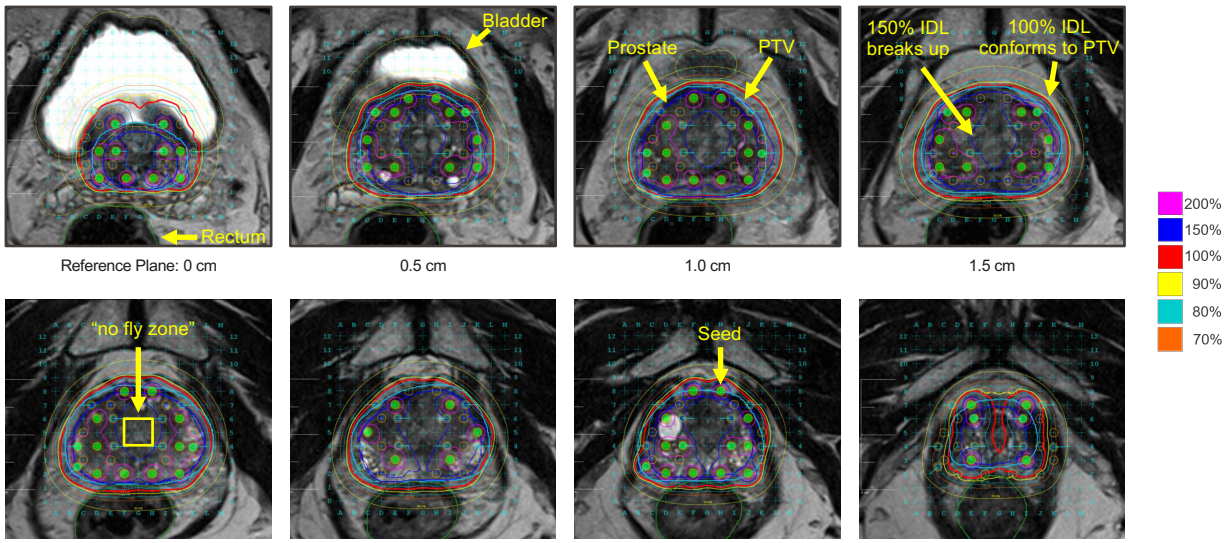

Reference Plane: 0 cm | 0.5 cm | 1.0 cm | 1.5 cm

2.0 cm | 2.5 cm | 3.0 cm | 3.5 cm

Initial MR → Pre-Planning → **Physics & QA** → Implant → Post-procedure

- Nomogram for quality assurance depends upon
  - Isotope
  - Prescription (monotherapy, boost, salvage)
  - Treatment-planning method
- Compared with US-based plans, MRI-based plans require less activity per volume[1]
- Quality assurance of pre-loaded needles
  - Needles arrive sterilized and pre-loaded
  - Compare treatment planning system needle-loading pattern with radiographs
  - Performed (1) at time of assay review and (2) at the start of implant procedure

Patient Information			
Patient Name:		MR Number:	
Physician:		Date of Implant:	2/2/2022
Pre-Plan			
Isotope:	○ I-125 Theragenics ● I-125 IsoAid ○ Pd-103 Theragenics ○ Cs-131 IsoRay	Type of Treatment:	Monotherapy
Prescribed Dose:	144 Gy	MRI Marker:	Yes
Activity at Implant Date:	0.391 mCi		
Prostate Volume:	40.11 cc		
# Needles in Plan:	27	# Seeds in Plan:	83
Extra Needles:	Quantity		
1 x 1 seed	0	Total # of extra needles:	2
1 x 2 seeds	1	Total # of extra seeds:	5
1 x 3 seeds	1	Extra needles (total):	1 x 2 seeds, 1 x 3 see
Ordered By:			
Date Ordered:	1/18/2022	1/18/2022	
Delivery Date to Hospital:	1/31/2022	<-- override here if needed	
# QA Seeds:	4		
Extra Needles:	1 x 2 seeds, 1 x 3 seeds.	# Extra Preloaded Seeds :	5
# Needles (Total):	29	# Seeds (Total):	92
Nomogram			
Total Activity from Fitting:	40.83 U		
Total Activity Actual:	41.22 U	Percent Difference:	1.0%
Seed Assay			
Save-to Folder:	S:\SHARED\Radiation Physics\Brachy		

1. Hanania et al., Brachytherapy 19 (2020) 38-42

Initial MR → Pre-Planning → **Physics & QA** → Implant → Post-procedure

- Nomogram for quality assurance depends upon
  - Isotope
  - Prescription (monotherapy, boost, salvage)
  - Treatment-planning method
- Compared with US-based plans, MRI-based plans require less activity per volume[1]
- Quality assurance of pre-loaded needles
  - Needles arrive sterilized and pre-loaded
  - Compare treatment planning system needle-loading pattern with radiographs
  - Performed (1) at time of assay review and (2) at the start of implant procedure

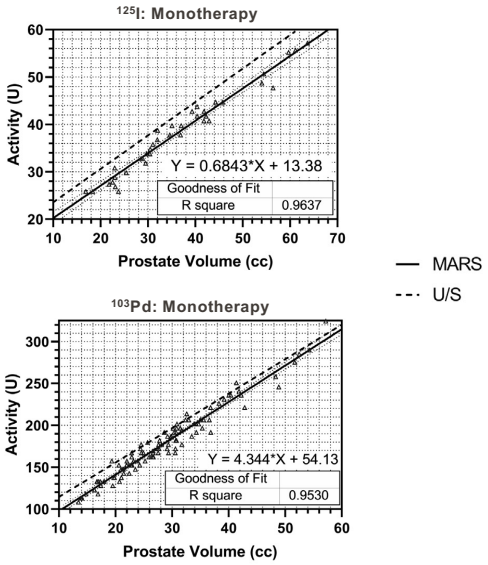

1. Hanania et al., Brachytherapy 19 (2020) 38-42

Initial MR → Pre-Planning → **Physics & QA** → Implant → Post-procedure

- Nomogram for quality assurance depends upon
  - Isotope
  - Prescription (monotherapy, boost, salvage)
  - Treatment-planning method
- Compared with US-based plans, MRI-based plans require less activity per volume[1]
- Quality assurance of pre-loaded needles
  - Needles arrive sterilized and pre-loaded
  - Compare treatment planning system needle-loading pattern with radiographs
  - Performed (1) at time of assay review and (2) at the start of implant procedure

Needle-loading pattern

Needle Number	Retractio (cm)	Hole Location	Seed Count
1	0.5	F, 8	4
2	0.5	H, 8	4
3	0.5	C, 7	2
4	0.5	E, 7	4
5	0.5	I, 7	4
6	0.5	K, 7	2
7	1	D, 6	3
8	0	F, 6	2
9	0	H, 6	2
10	1	J, 6	3
11	0.5	C, 5	3
12	0.5	K, 5	3
13	1	B, 4	2
14	0	D, 4	4
15	0	F, 4	2

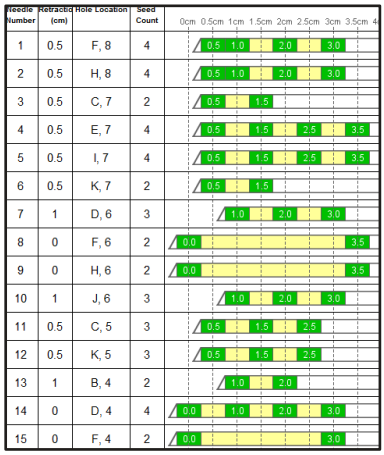

Radiograph



1. Hanania et al., Brachytherapy 19 (2020) 38-42

Initial MR → Pre-Planning → Physics & QA → **Implant** → Post-procedure

Ambulatory Care Building Facilities

PACU

Brachytherapy CT OR vault

Initial MR → Pre-Planning → Physics & QA → **Implant** → Post-procedure

TRUS-MRI Fusion

- Fusion is required between
  - MRI used for pre-planning
  - TRUS used intraoperatively for needle placement
- Cognitive fusion based on multiple anatomic landmarks[1]
  1. Urethra at prostate base (catheter is present for US)
  2. External urinary sphincter at prostate apex
  3. Posterior and lateral edges of prostate align with grid
- Fusion is performed (1) at start of procedure and (2) throughout the implant

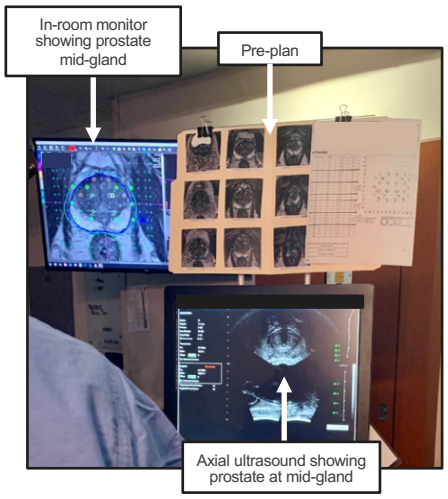

1. Blanchard et al., Brachytherapy 16 (2017) 734 - 42

Initial MR → Pre-Planning → Physics & QA → **Implant** → Post-procedure

CT verification scan

- Performed while patient is still under anesthesia
- Patient is flat in FFS orientation
  - Scout is compared with 3D rendering from treatment planning system
  - CT scan is an initial assessment of implant quality
- May be fused with Day 0 MRI if needed for seed localization

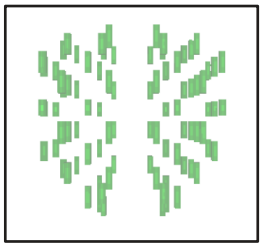

3D rendering

CT scout

Initial MR → Pre-Planning → Physics & QA → **Implant** → Post-procedure

CT verification scan

- Performed while patient is still under anesthesia
- Patient is flat in FFS orientation
  - Scout is compared with 3D rendering from treatment planning system
  - CT scan is an initial assessment of implant quality
- May be fused with Day 0 MRI if needed for seed localization

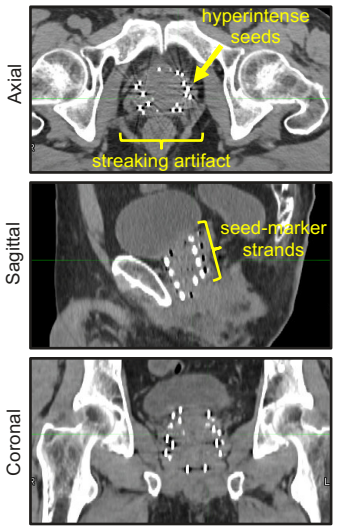

Post-implant CT

Initial MR → Pre-Planning → Physics & QA → Implant → **Post-procedure**

Day 0 MRI scan

- Single scan
  - Performed in diagnostic radiology
  - Axial 3D FIESTA-C_CISS
  - Provides soft tissue contrast with visualization of C4 markers
- Use an in-house detection algorithm to identify location of implanted sources
  - Permits use of only MRI for post-treatment planning
  - MRI/CT may be fused if needed

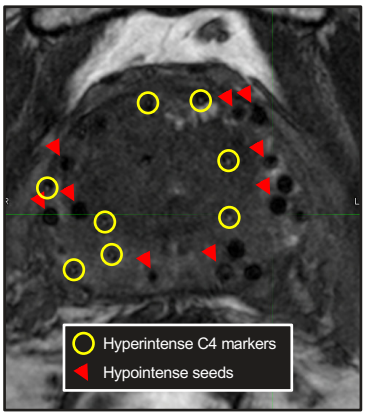

Day 0 post-implant MRI

Initial MR → Pre-Planning → Physics & QA → Implant → **Post-procedure**

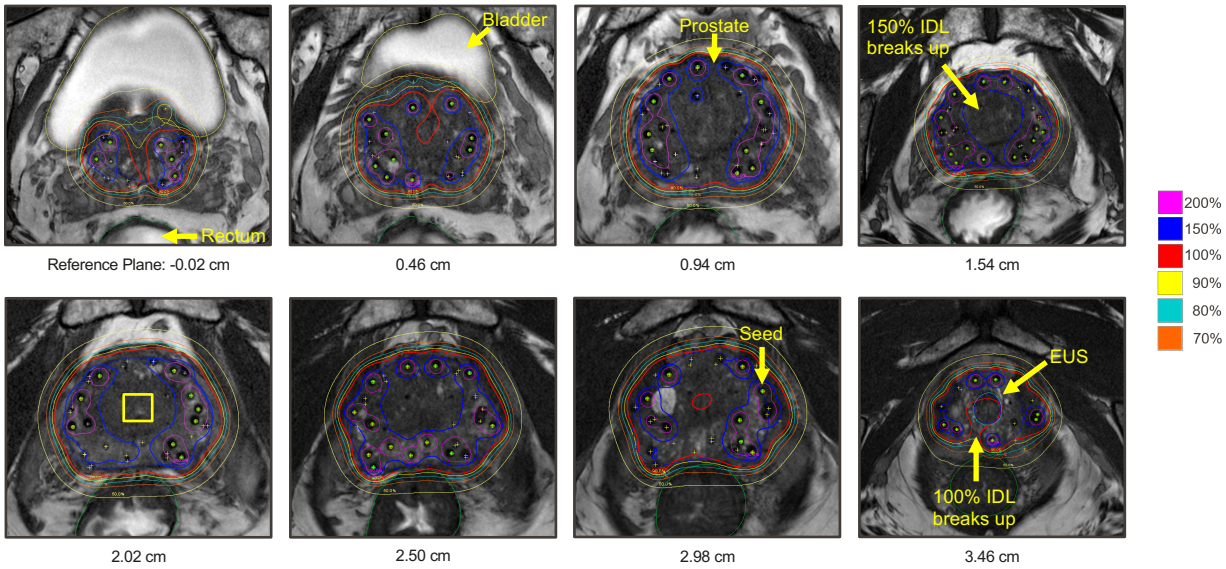

Reference Plane: -0.02 cm | 0.46 cm | 0.94 cm | 1.54 cm

2.02 cm | 2.50 cm | 2.98 cm | 3.46 cm

Initial MR → Pre-Planning → Physics & QA → Implant → **Post-procedure**

Opportunities for modifying implant

- Once all planned seeds have been placed
- After reviewing intraoperative CT scan
- After Day 0 MRI scan
  - Order additional needles and schedule follow-up procedure
  - Inadequate coverage: D90 < 90%
  - Excessive edema: 30 – 40 %
- Option to perform a Day 30 treatment planning if needed

Dosimetrist modifying plan intraoperatively

Summary

1. Understand the roles various imaging modalities may have in a low dose rate prostate seed implant program
   - MRI
   - TRUS
   - CT
2. Recognize some of the benefits of MRI-based planning over traditional CT or US-based planning
3. Describe considerations for implementing MRI-based treatment planning

Summary

1. Understand the roles various imaging modalities may have in a low dose rate prostate seed implant program
2. Recognize some of the benefits of MRI-based planning over traditional CT or US-based planning
   - Superior soft tissue contrast
   - Reduced contouring uncertainties
   - Delineation of structures not visible on CT or US
   - Improved seed localization accuracy
3. Describe considerations for implementing MRI-based treatment planning

Summary

1. Understand the roles various imaging modalities may have in a low dose rate prostate seed implant program
2. Recognize some of the benefits of MRI-based planning over traditional CT or US-based planning
3. Describe considerations for implementing MRI-based treatment planning
   - Methods to assess PAI
   - Use of virtual simulation to account for deflection of prostatic apex
   - TRUS/MRI cognitive fusion
   - Choice of fusion with CT for post-planning
   - Use of positive contrast markers for seed localization

Acknowledgements

- **Radiation Oncologists**
  - Steven Frank, MD
  - Henry Mok, MD
  - Chad Tang, MD
- **Radiologist**
  - Aradhana Venkatesan, MD
  - Tharakeswara Bathala, MD
- **Brachytherapy Dosimetrists**
  - Christine Starks, CMD
  - Mandy Cunningham, CMD
  - Edwin Santiago, CMD
- **Therapy Medical Physicists**
  - Weiliang Du, PhD
  - Rajat Kudchadker, PhD
  - Surendra Prajapati, PhD
  - Samantha Simiele, PhD
  - Jihong Wang, PhD
- **Imaging Medical Physicists**
  - Jerimiah Sanders, PhD
  - Jingfei Ma, PhD
- **Research Dosimetrist**
  - Teresa Bruno, CMD